Open Access
p-ISSN 2684-6748
e-ISSN 2656-9825

RESEARCH ARTICLE

Saffron and folic acid mitigate hepatic structural damage in IUGR rats via modulation of oxidative stress markers: A histological and molecular study

Nur Aini Hasan [1,2], Viskasari Pintoko Kalanjati [3,4], Iswandi Erwin [5,6], Lucky Prasetiowati [3,6], Joni Susanto [3], Muhammad Miftahussurur [7,8]

[1]Master of Basic Medical Sciences in Anatomy and Histology, Faculty of Medicine, Universitas Airlangga, Surabaya, Indonesia
[2]Department of Anatomy and Histology, Faculty of Medicine, Universitas Muhammadiyah Sidoarjo, Sidoarjo, Indonesia
[3]Department of Anatomy, Histology and Pharmacology, Faculty of Medicine, Universitas Airlangga, Surabaya, Indonesia
[4]School of Postgraduate-Sekolah Pascasarjana, Universitas Airlangga, Surabaya, Indonesia
[5]National Brain Center Hospital Prof. Dr. dr. Mahar Mardjono, Jakarta, Indonesia
[6]Doctor of Medicine Program, Faculty of Medicine, Universitas Airlangga, Surabaya, Indonesia
[7]Helicobacter pylori and Microbiota Study Group, Institute of Tropical Disease, Universitas Airlangga, Surabaya, Indonesia
[8]Division of Gastroentero-Hepatology, Department of Internal Medicine, Faculty of Medicine-Dr. Soetomo General Academic Hospital, Universitas Airlangga, Surabaya, Indonesia

Correspondence:
Viskasari Pintoko Kalanjati
Department of Anatomy, Histology and Pharmacology, Faculty of Medicine, Universitas Airlangga, Surabaya – 60132, Indonesia

Email: viskasari-p-k@fk.unair.ac.id

Article history:
Received: 2025-08-15
Revised: 2026-03-12
Accepted: 2026-06-05
Available online: 2026-09-02

Keywords:
Fetal growth restriction
Folic acid
Neonatal mortality
Pregnancy
Saffron

https://doi.org/10.33086/ijmlst.v8i2.7919

Abstract

Maternal malnutrition during pregnancy is a major contributor to intrauterine growth restriction (IUGR) in Indonesia and is associated with fetal programming of hepatic inflammation and structural liver injury. While folic acid supplementation is routinely recommended during pregnancy, alternative nutritional interventions with antioxidant properties, such as saffron (*Crocus sativus* L.), have gained attention. However, their comparative effects on hepatic inflammation and histopathological changes in IUGR remain unclear. This study aimed to evaluate the effects of maternal saffron administration compared with folic acid on birth weight, hepatic tumor necrosis factor-alpha (TNF-α) expression, and liver histopathology in an experimental IUGR rat model. Forty female and eight male rats were mated, and pregnant dams were randomly assigned to four groups: normal control (standard diet), IUGR control (50% dietary restriction), IUGR + saffron (15.68 mg/kg BW), and IUGR + folic acid (1.5 mg/kg BW) administered throughout pregnancy and lactation. After 21 days of lactation, offspring were euthanized and liver tissues were analyzed using histopathology and immunohistochemistry for TNF-α expression. Dietary restriction significantly reduced birth weight and increased hepatic TNF-α expression and liver injury compared with the normal control group ($p < 0.05$). Both saffron and folic acid significantly improved birth weight, reduced TNF-α expression, and attenuated histological damage compared with the IUGR control group ($p < 0.05$), with folic acid demonstrating greater improvement. These findings suggest that maternal supplementation with saffron and folic acid may attenuate hepatic inflammation and structural liver injury in IUGR, with folic acid showing a stronger protective effect in this model.

Citation: Hasan NA, Kalanjati VP, Erwin I, Prasetyowati L, Susanto J, Miftahussurur M. Saffron and folic acid mitigate hepatic structural damage in IUGR rats via modulation of oxidative stress markers: A histological and molecular study. Indones J Med Lab Sci Technol. 2026;8(2):96–109. https://doi.org/10.33086/ijmlst.v8i2.7919

This is an open access article distributed under the Creative Commons Attribution-ShareAlike 4.0 International License, which permits unrestricted use, distribution, and reproduction in any medium, provided the original work is properly cited. ©2026 The Author(s).

1. INTRODUCTION

Intrauterine Growth Restriction (IUGR) is a pathological state in which the fetus does not reach its genetically predetermined growth potential, usually being defined as having a birth weight below the 10th percentile for the gestational age (1). This pregnancy complication is linked to impaired development and function of the fetal organs. IUGR raises the chance of preterm birth, stillbirth, neonatal morbidity, and long-term metabolic disorders, such as cardiovascular disease and type 2 diabetes mellitus (2). There is now evidence showing that IUGR leads to long-term metabolic programming, impacting vital organs like the liver and making the offspring susceptible to metabolic dysfunction later in life (3).

The rate at which IUGR occurs all over the world differs greatly, there being strong variations between high-income countries and those that have a low or middle socioeconomic status. In areas with a high socioeconomic status the rate of IUGR is about 3–9%, whereas in areas of lower socioeconomic status it can go as high as 30%. In developing regions maternal undernutrition is a major risk factor since insufficient intake of nutrients hampers placental function and thus limits fetal growth. In Indonesia the neonatal mortality rate linked to IUGR is 44.7/1,000 live births, and about 61% of the infants affected die within the first 90 days of life. Moreover, 66.2% of neonatal deaths take place among babies weighing less than 2,500 grams, many of whom are either IUGR cases or premature (1,4). These epidemiological figures show how urgently effective prenatal nutritional interventions are needed in order to reduce the bad outcomes of IUGR.

On a mechanistic level, it has been found that IUGR is linked to increased oxidative stress and inflammatory signaling, both of which lead to structural and metabolic disorders of the liver (5). Experimental studies have shown that fetuses suffering from IUGR become insulin resistant in the liver while in the uterus, leading to higher levels of glucose production in the liver and an increased risk of developing type 2 diabetes and non-alcoholic fatty liver disease (NAFLD) later in life (6). In IUGR, inflammatory mediators, especially tumor necrosis factor-alpha (TNF-α), are often elevated and are connected to the activation of inflammatory transcription pathways such as nuclear factor kappa B (NF-κB). The activation of these pathways causes oxidative stress, vascular inflammation and tissue damage (7). This mechanism is at the heart of the development of placental dysfunction, encompassing both preeclampsia and IUGR. Activation of NF-κB results in oxidative stress, vascular inflammation and endothelial dysfunction, all of which worsen placental insufficiency and fetal growth restriction (1,8).

Folic acid is necessary for DNA synthesis and methylation via one-carbon metabolism and has been found to reduce oxidative stress and inflammatory reactions in cases of pregnancy complications (9,10). Because it affects the availability of methyl donors, folic acid can influence the regulation of genes that are involved in inflammatory and metabolic pathways and thus contribute to improved placental and fetal outcomes (11). In Indonesia folic acid supplementation is routinely recommended as part of antenatal care because of its proven benefits for both maternal and fetal health (12,13).

Aside from taking conventional supplements, natural bioactive compounds have recently been regarded as possible complementary methods for the management of inflammatory and metabolic disorders. Saffron (*Crocus sativus* L.) contains a number of bioactive components, such as crocin, crocetin, and safranal, which have shown antioxidant and anti-inflammatory effects in experimental studies (14,15). It has been stated that these compounds are able to decrease oxidative stress and affect inflammatory mediators including TNF-α and other pro-inflammatory cytokines (16–18). As a result, saffron might have the potential to lessen the inflammatory and oxidative processes linked with nutrient restriction during pregnancy.

Saffron was chosen for this study not only because of its biological properties, but because of the strong antioxidant and anti-inflammatory effects of its active compounds, namely crocin, crocetin, and safranal, which could help counteract the oxidative stress and inflammatory pathways involved in the development of IUGR. There is now evidence to indicate that saffron might act as a promising nutraceutical for disorders characterized by chronic inflammation and oxidative tissue damage. This is especially pertinent in Southeast Asia, where maternal undernutrition is a major public health problem and a key factor in poor fetal growth. Even though folic acid remains the standard prenatal supplement because of its low cost, proven effectiveness, and wide availability, looking at the effects of saffron when used together with folic acid could provide useful information about the possible role of other bioactive substances in reducing hepatic injury linked to IUGR (19,20).

The potential of saffron to reduce hepatic injury and inflammatory responses in cases of IUGR has still not been adequately investigated. Furthermore, there are very few studies that have directly compared the effects of saffron with well-established prenatal interventions such as folic acid in experimental models of IUGR. For this reason, the present study was carried out with the aim of looking at the effects of giving saffron to the mother as opposed to giving folic acid on birth weight, the expression of TNF-α in the liver, and the liver histopathology in a rat model of IUGR induced by diet. On the basis of these results, the study hopes to give some early indications as to the possible value of saffron as a complementary nutritional intervention for reducing the hepatic inflammation and structural damage associated with IUGR. We believed that giving the mothers saffron would lead to a reduction in hepatic inflammation and structural liver damage in the offspring of the IUGR rats, even if its effects were different from those of folic acid.

2. MATERIALS AND METHODS

The Local Ethics Committee for animal experiments at Universitas Airlangga approved the study (approval number 290/EC/KEPK/FKUA/2023). Forty adult female Wistar albino rats (8–10 weeks old) and eight adult male rats were obtained from the Faculty of Veterinary Medicine, Universitas Airlangga, Surabaya, Indonesia. Each experimental group consisted of 10 pregnant does (n = 10 each group). To prevent pseudo-replication and ensure statistical independence, one pup from each litter was randomly selected for histological and molecular analysis. Sample size was determined based on previous studies investigating dietary-restriction-induced intrauterine growth restriction (IUGR) and hepatic inflammatory responses in rodent models, which used similar group sizes to detect significant differences in birth weight and inflammatory markers. Animals were housed under controlled conditions: temperature at 22 ± 2 °C, relative humidity at 55 ± 10%, and a 12:12 hour light/dark cycle. During acclimatization, rats were housed individually in polycarbonate cages with ad libitum access to food and water. After pregnancy confirmation, does remained under these conditions. For mating, females were paired with males at a 2:1 ratio following a 7-day acclimatization period. Vaginal plugs were checked daily at 7:00 a.m., and cages were inspected for dislodged plugs. The day a vaginal plug was detected was designated as gestational day 0. Pregnant does were randomly assigned to experimental groups using a computer-generated random number sequence (21,22).

To minimize observational bias, personnel conducting histopathological scoring and immunohistochemical analysis were blinded to group assignments during data acquisition and analysis. Intrauterine growth restriction (IUGR) was induced by restricting the maternal diet to 50% of the normal daily intake. This approach is a well-established experimental model for fetal growth restriction and metabolic programming in rodents, as it leads to placental insufficiency and impaired fetal growth (12,13).

2.1. Pharmacological Agents and Experimental Design

This study (Figure 1) utilized a controlled *in vivo* design involving pregnant Wistar rats (*Rattus norvegicus*) to develop an intrauterine growth restriction (IUGR) model through maternal dietary restriction (23). Female rats aged 8–10 weeks were mated with males of the same strain (21,22). When the pregnancies were confirmed, the dams were at random allocated to four groups: 1) the control group (given the standard diet), 2) the IUGR group (with a 50% restriction of their diet), 3) the IUGR group treated with folic acid, and 4) the IUGR group treated with saffron extract. Each group included 10 pregnant dams (n = 10 dams each group), and from each litter one pup was randomly chosen for analysis in order to ensure statistical independence.

The IUGR model was produced by offering 50% of the standard diet (15 g/day) *ad libitum* from gestational day 1 to day 21, using BR-1 standard pellets (Pokphand 511, Indonesia) which contained 21–23% protein, 5–8% fat, and 2,800–3,100 kcal/kg (11,23). Drinking water was provided *ad libitum* from a municipal supply.

The saffron extract was obtained from Piping Rock® Supreme Saffron Extract (88.5 mg/capsule, 2:1 extract equivalent to 177 mg saffron stigma) and was standardized to contain the active compounds crocin, safranal, and picrocrocin. A suspension was made fresh each day in a mixture of 0.5% carboxymethylcellulose sodium (CMC-Na) and distilled water. Folic acid (Novapharin Pharmaceutical Industries, Indonesia) was also suspended in a CMC-Na solution. All the groups, including the control group, received the same vehicle in order to rule out any effects of the solvent.

Both substances were given once a day by oral gavage at a volume of 1 mL/200 g of body weight. The saffron extract was administered at a dose of 15.68 mg/kg body weight / day, this being calculated from the human equivalent dose (177 mg/70kg/day) and adjusted for rats (24). Folic acid was given at a dose of 1.5 mg/kg body weight per day, this being derived from the effective dose in mice of 3 mg/kg/day using standard methods for translating doses between species (13,25). These doses were chosen on the basis of previous evidence regarding both efficacy and safety and stay well below the reported toxicity levels.

2.2. Histological Preparation

On day 21 after birth the pups were euthanized by cervical dislocation, a technique which is regarded as suitable for use on small rodents in line with the AVMA guidelines and one that was carried out solely by qualified personnel. After euthanasia the liver tissues were carefully removed, and samples were consistently taken from the central area of the right hepatic lobe in order to ensure reproducibility. Each sample was then processed in the same way.

The tissues were left in 10% neutral-buffered formalin for 24 to 48 hours, then dehydrated by means of an ethanol series of increasing concentration, cleared in xylene and embedded in paraffin blocks. Sections 5 µm thick were cut with a rotary microtome, placed on slides which had been coated with poly-L-lysine, and stained using hematoxylin and eosin (H&E). The histopathological evaluation was carried out under light microscopy by two separate observers who were blinded to the case details.

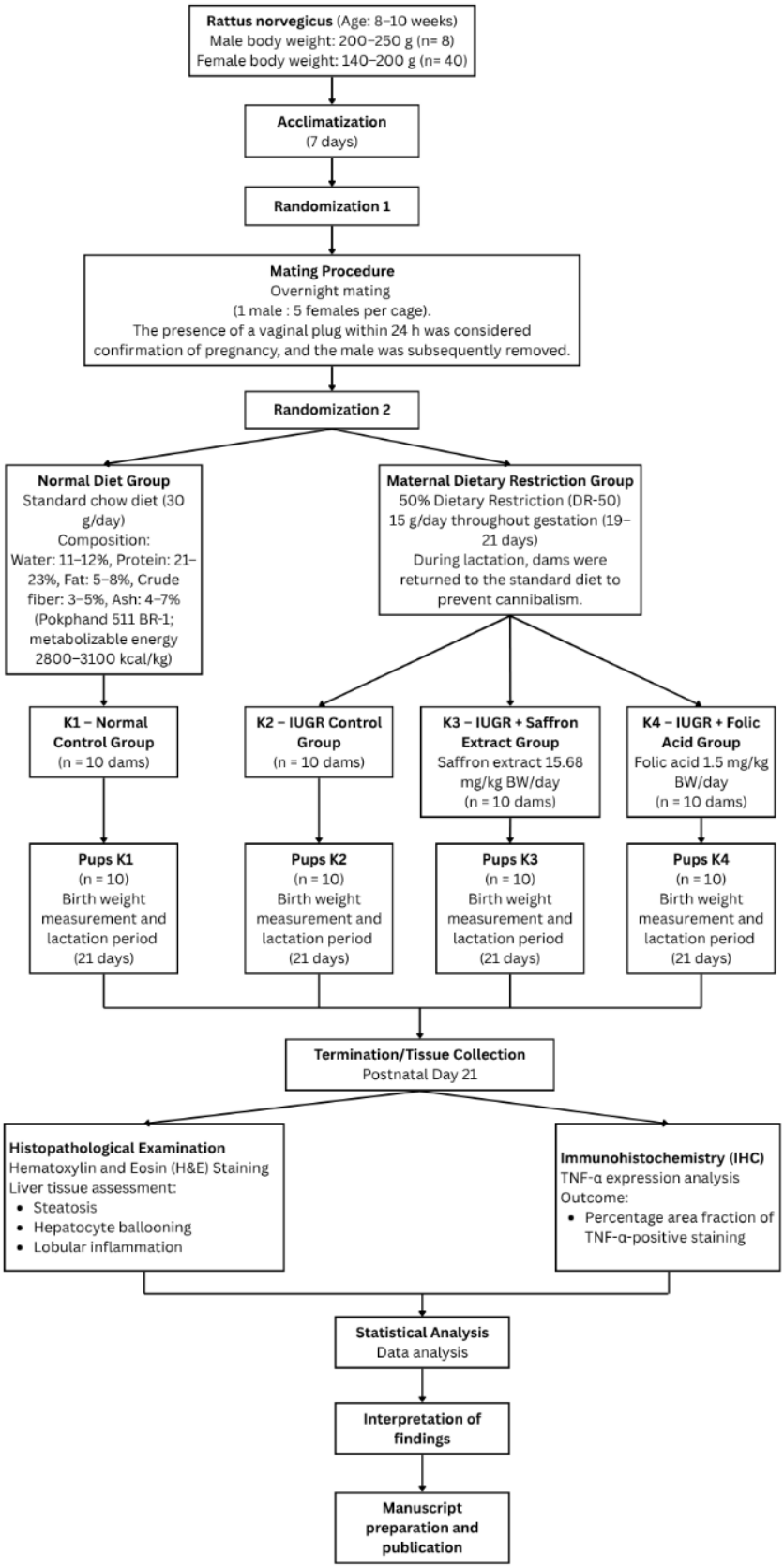

Figure 1. Experimental design of the study. Female Rattus norvegicus were randomly assigned to either a normal diet or a 50% dietary restriction regimen during pregnancy to induce intrauterine growth restriction (IUGR). IUGR dams received either no treatment, saffron extract (15.68 mg/kg body weight/day), or folic acid (1.5 mg/kg body weight/day). Offspring were monitored until postnatal day 21. Liver tissues were subsequently collected for histopathological evaluation using hematoxylin and eosin staining and immunohistochemical analysis of TNF-α expression

2.3. Liver Morphological Evaluation

The liver tissues were examined using a light microscope by two separate observers who were unaware of the details of the cases. To determine the extent of hepatic injury, the NAFLD Activity Score (NAS) was applied, this being a semi-quantitative scoring method developed by Kleiner et al. (26). The NAS looks at three main histopathological features: steatosis, hepatocyte ballooning, and lobular inflammation. Each of these features is assessed according to defined criteria, and the total NAS is calculated by adding up the individual scores, thus giving a combined score that ranges from 0 to 8. The higher the NAS, the more severe the liver damage (27,28). Steatosis shows how much fat has accumulated in the hepatocytes, ballooning is a sign of hepatocellular degeneration, and lobular inflammation means that there is an infiltration of inflammatory cells into the liver lobules. In this study, the NAS was used to compare the liver histopathology among the various treatment groups. A lower NAS score meant that the liver architecture had been better preserved and there was less damage, while a higher score indicated more advanced pathological changes in keeping with NAFLD (3,29).

2.4. Biochemical Evaluations

Liver sections (5 µm) underwent deparaffinization in xylene (three times for 5 minutes each), followed by rehydration through graded ethanol (absolute and 70%, 3 minutes each) and rinsing in distilled water. Endogenous peroxidase activity was quenched using 3% hydrogen peroxide for 10 minutes at room temperature, followed by phosphate-buffered saline (PBS) washes. Antigen retrieval was conducted with a 0.025% trypsin solution at 37 °C for 15 minutes. Non-specific binding was blocked using Ultra V Block (Thermo Scientific, USA) for 10 minutes at room temperature. Sections were incubated with mouse monoclonal anti-TNF-α antibody (No. Cat. bms-0387M, clone 1F6, Bioss Inc., USA) at a 1:250 dilution in PBS for 35 minutes at room temperature. After PBS washes, slides were incubated with HRP-conjugated polymer secondary antibody (Thermo Scientific, USA) for 35 minutes at room temperature in the dark. Visualization was performed with DAB chromogen (20µL/1mL substrate buffer) for 10 minutes, followed by counterstaining with Mayer's hematoxylin for 3 minutes. Slides were then rinsed, dehydrated, mounted, and examined under a light microscope.

TNF-α immunohistochemical expression was quantified using ImageJ software (NIH, USA) as previously described (29,30). For each slide, five non-overlapping high-power fields (400×) were captured. Images were converted to 8-bit grayscale, and the region of interest (ROI) was defined to include hepatocyte cytoplasm and nuclei. The threshold was adjusted to distinguish positive DAB staining from background, and the percentage of positive-stained area was calculated using the "Color Deconvolution" plugin (H DAB vector). The mean optical density (MOD) of DAB staining was measured to represent the relative expression level of TNF-α. All measurements were conducted in a blinded manner by two independent observers. Body weights of dams and pups were measured using two digital scales: the SF-400 large-capacity scale (maximum 10 kg) for adult rats and the TN-series Mini Digital Scale (maximum 50 g, readability 0.001 g) for neonates.

2.5. Statistical Analyses

The litter (dam) was designated as the unit of analysis (n), and one pup per litter was randomly selected for statistical evaluation to avoid pseudo-replication. Ratio data for dependent variables, such as birth weight (BW), organ index, and hepatic TNF-α expression, were presented as mean ± standard deviation (SD) for parametric data or as median [interquartile range] for non-parametric data.

Liver histopathological scoring was performed semi-quantitatively using ImageJ software (NIH, USA). Steatosis was assessed as the percentage of lipid vacuolization at 400× magnification, lobular inflammation as the number of inflammatory foci / visual field at 200× magnification, and hepatocyte ballooning as the number of ballooned hepatocytes per visual field at 400× magnification. The sum of these parameters constituted the NAFLD Activity Score (NAS). For immunohistochemistry (IHC), ImageJ with the Color Deconvolution plugin was employed to separate DAB staining. Five non-overlapping fields per section were analyzed at 400× magnification to quantify the percentage of positively stained area and mean optical density (MOD), reflecting TNF-α expression.

Assumption testing was performed using the Shapiro–Wilk test for normality ($p > 0.05$) and Levene's test for homogeneity of variance ($p > 0.05$) in SPSS version 25.0 (IBM Corp., 2017). Parametric data were compared between groups using one-way analysis of variance (ANOVA) followed by the Least Significant Difference (LSD) post-hoc test. Non-parametric data were analyzed using the Kruskal–Wallis test and the Mann-Whitney U test for pairwise comparisons. Statistical significance was defined as $p < 0.05$ (95% confidence level). The LSD post-hoc test was selected due to the limited number of experimental groups and the primary aim of identifying specific differences between treatment groups following a significant ANOVA result. This approach is frequently applied in controlled experimental animal studies with predefined group comparisons.

3. RESULTS AND DISCUSSION

3.1. Descriptive Analysis of Birth

Intrauterine Growth Restriction (IUGR) is a condition in which the fetus fails to grow optimally in utero, often resulting in low birth weight. In this study, birth weight below the 10th percentile was used as a reference for identifying IUGR. Using an animal model of IUGR, the study aimed to investigate how dietary interventions and supplementation could influence birth weight and support fetal development (2). Referring to the IUGR control group, which consistently showed lower birth weight compared to other groups (below the 10th percentile), the results indicate successful induction of IUGR through dietary restriction (3,23).

The study included four groups of rats, each being subjected to different treatment conditions: one normal control group fed a standard diet, one IUGR control group given a diet reduced by 50 percent, another IUGR group supplied with saffron extract at a dose of 15.68 mg/kg of body weight/day, and a fourth IUGR group given folic acid at a dose of 1.5 mg/kg of body weight per day. The body weights of the pups were recorded from birth up to postnatal day 22. The findings indicated that the pups in the IUGR control group, on the 50 percent restricted diet, always had birth weights below the 10th percentile, thus verifying that dietary restriction is effective in producing an IUGR model. This is in agreement with earlier studies which have shown that prenatal nutritional restriction results in a lower birth weight and IUGR (6,31,32).

Figure 2 shows the trends in the birth weight (BW) of the pups, which have been divided into four groups (K1, K2, K3, and K4). The dashed line indicates the 10th percentile and is used as a reference point for detecting IUGR. The birth weights of the pups in group K2 (shown by the gray line) are continually below the 10th percentile, which means that the average BW in group K2 is less than that of the other groups. This confirms that maternal dietary restriction successfully induced an IUGR animal model.

Normality was tested using the Shapiro-Wilk test, and homogeneity was assessed with Levene's test. The Shapiro-Wilk test showed that all birth weight (BW) data were not normally distributed ($p < 0.05$). Therefore, a non-parametric Kruskal-Wallis test was conducted. The Kruskal-Wallis analysis yielded a significant result ($p < 0.001$), indicating a statistically significant difference in the mean birth weight of pups among the four groups: normal control (K1), IUGR control (K2), IUGR + saffron (K3), and IUGR + folic acid (K4). This suggests that at least one group had a significantly different mean birth weight compared to the others.

Based on Figure 3, the most significant difference in birth weight was observed between group K1 and K2, as K2 represents the IUGR control group with birth weights below the 10th percentile. However, no significant difference was found between K1 and K4, indicating that birth weight in the IUGR + folic acid group approached that of the normal group. Significant differences were also observed between K2 and both K3 and K4, suggesting that administration of saffron and folic acid led to improved birth weights compared to the IUGR control. Furthermore, no significant difference was found between K3 and K4, indicating that saffron may have a comparable potential to folic acid in improving birth weight in IUGR pups.

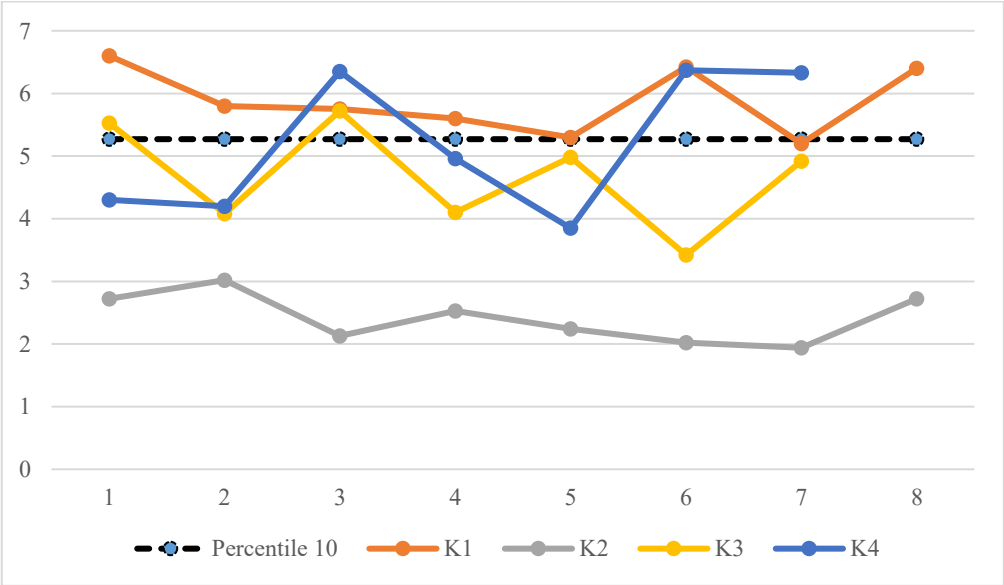

Figure 2. Birth weight (BW) trend of pups in groups K1–K4 with 10th percentile.

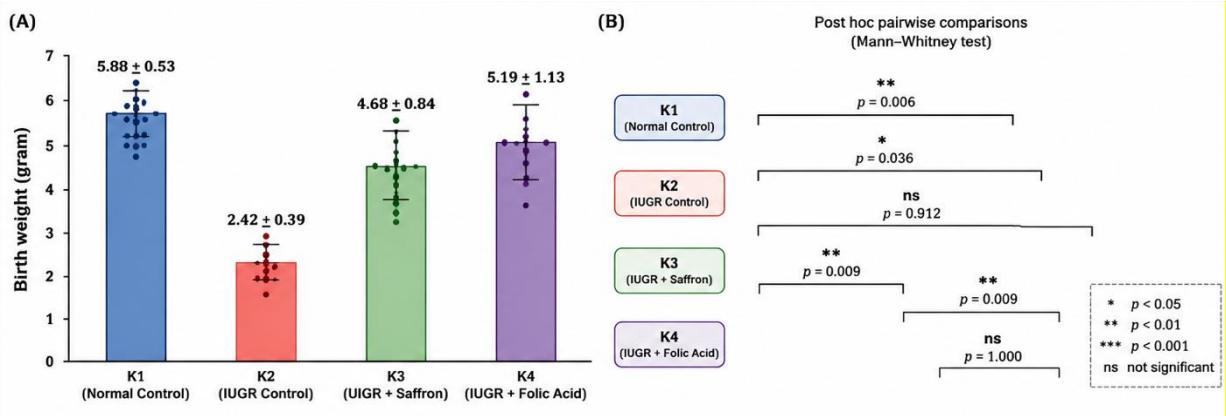

Figure 3. Birth weight among experimental groups. Data are presented as mean ± SD. Significant differences among groups were determined by The Kruskal-Wallis test (p< 0.001)

In contrast, pups in the normal control group exhibited normal birth weights above the 10th percentile, indicating healthy, unrestricted growth. Meanwhile, IUGR pups receiving saffron or folic acid supplementation demonstrated significant improvements in birth weight compared to the IUGR control group. Saffron, which contains bioactive compounds such as safranal, crocetin, and crocin, exerts antioxidant and anti-inflammatory effects that help reduce oxidative stress and placental inflammation, thereby improving nutrient supply to the fetus (33). Hepatic inflammation and structural damage may impair metabolic homeostasis, nutrient processing, and energy balance, which could contribute to reduced body weight in IUGR animals (34,35). Recent meta-analyses have confirmed crocin's potent antioxidant and anti-inflammatory effects, reporting significant reductions in TNF-α and IL-6 levels, as well as improvements in overall antioxidant capacity (36). Similarly, folic acid supplementation has been shown to lower pro-inflammatory cytokines in a dose-responsive manner (37). Additionally, saffron's antioxidative efficacy—evident in lowering oxidative stress markers such as MDA and enhancing TAC—has been validated in recent clinical evidence (38).

The amount of nutrients that a mother takes in while she is pregnant—particularly protein—has a vital impact on the survival, growth and development of the embryo. If a mother consumes too little protein, embryonic death, intrauterine growth restriction and impaired postnatal growth may result from a deficiency of the essential amino acids needed for cellular metabolism and various physiological functions. The protein that the mother consumes has a direct effect on fetal programming and causes changes in gene expression within the fetal genome. Since L-arginine (Arg) is used as a precursor in the production of signalling molecules (such as nitric oxide, polyamines and creatine), it is important during pregnancy for fetal growth and development. Poor maternal protein intake can cause deficiencies of Arg and of other essential amino acids in both the mother and the fetus. Saffron, through its anti-inflammatory action, and folic acid, by means of DNA methylation pathways, have both been shown to be effective in reducing the negative effects of IUGR. This study confirms that nutritional interventions can play a crucial role in promoting healthy fetal growth and in lowering the risk of IUGR (12,18).

3.2. TNFα Expression in Liver Tissue Assessed by IHC Method

The data from this study show that in all the pup groups whose mothers underwent a 50% dietary restriction there was an increased expression of TNFα in the hepatic tissue (5). It has already been shown in earlier studies that intrauterine growth restriction (IUGR) causes systemic inflammation and oxidative stress, especially in the hepatic tissue. More recent findings indicate that IUGR neonates have altered hepatic NF-κB signaling and a reduced TNF-α–mediated acute inflammatory response when exposed to endotoxin, which suggests basic disruptions in liver immunity and in the regulation of oxidative stress (39). Metabolomic analysis of the livers of IUGR rats also points to a higher level of oxidative markers and to structural liver damage (40). Moreover, the epigenetic changes induced by hypoxia—such as increased histone acetylation in gene promoters—show how IUGR makes the liver more susceptible to persistent inflammation and to stress (41).

The analysis of TNFα expression in the liver tissue (Figure 4) showed that the K2 group had the highest levels of TNFα (mean ± SE), then the K3 group. The K4 group displayed lower levels, coming close to those observed in the K1 group which represent the normal condition. Since the Shapiro-Wilk test for normality (with $p < 0.05$) revealed that the data were not normally distributed, non-parametric tests were used, namely the Kruskal-Wallis test (Figure 4), and then a Mann-Whitney post-hoc analysis was carried out (Table 1). The pairwise differences between the groups were assessed using Mann-Whitney post-hoc tests as shown in Table 1. A highly significant difference ($p < 0.001$) was found in TNFα expression between the K1 and K2 groups, which shows that the rats on a dietary restriction regimen (K2) had substantially higher TNFα expression than the normal controls (K1).

A statistically significant difference ($p < 0.001$) was observed between the K1 and K3 groups. Although saffron administration reduced inflammation, TNFα expression in the K3 group remained higher than in the K1 group. The difference between K1 and K4 was also statistically significant ($p = 0.037$), but less pronounced than the difference observed between K2 and K3. A highly significant difference ($p < 0.001$) was found between K3 and K2, indicating that saffron significantly decreased TNFα expression compared to dietary restriction alone. Furthermore, a significant difference ($p < 0.001$) between the K2 and K4 groups demonstrated that folic acid substantially reduced TNFα expression and was more effective than saffron in reducing inflammation. A significant difference ($p < 0.001$) was also noted between the K3 and K4 groups. While both interventions reduced TNFα expression relative to the IUGR control group, the reduction in the folic acid group exceeded that in the saffron group. These findings suggest that folic acid may exert a stronger anti-inflammatory effect in this experimental model; however, the biological relevance of this difference should be interpreted with caution.

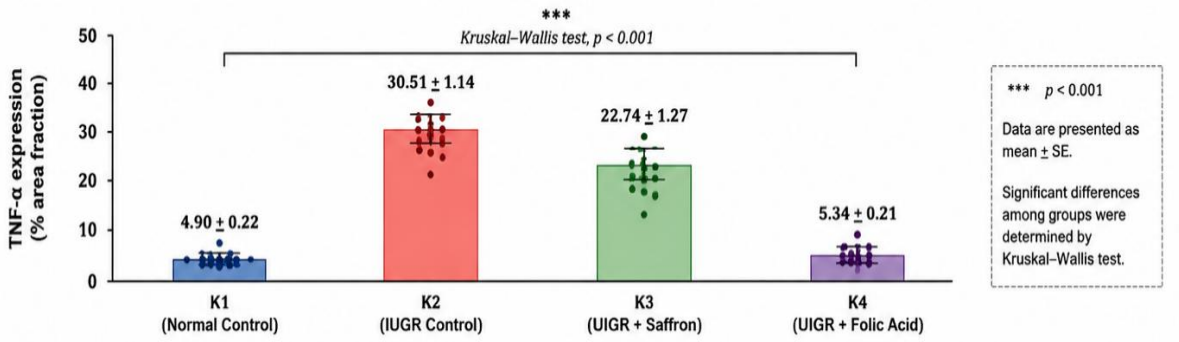

Figure 4. Quantification of TNF-α immunohistochemical staining among experimental groups

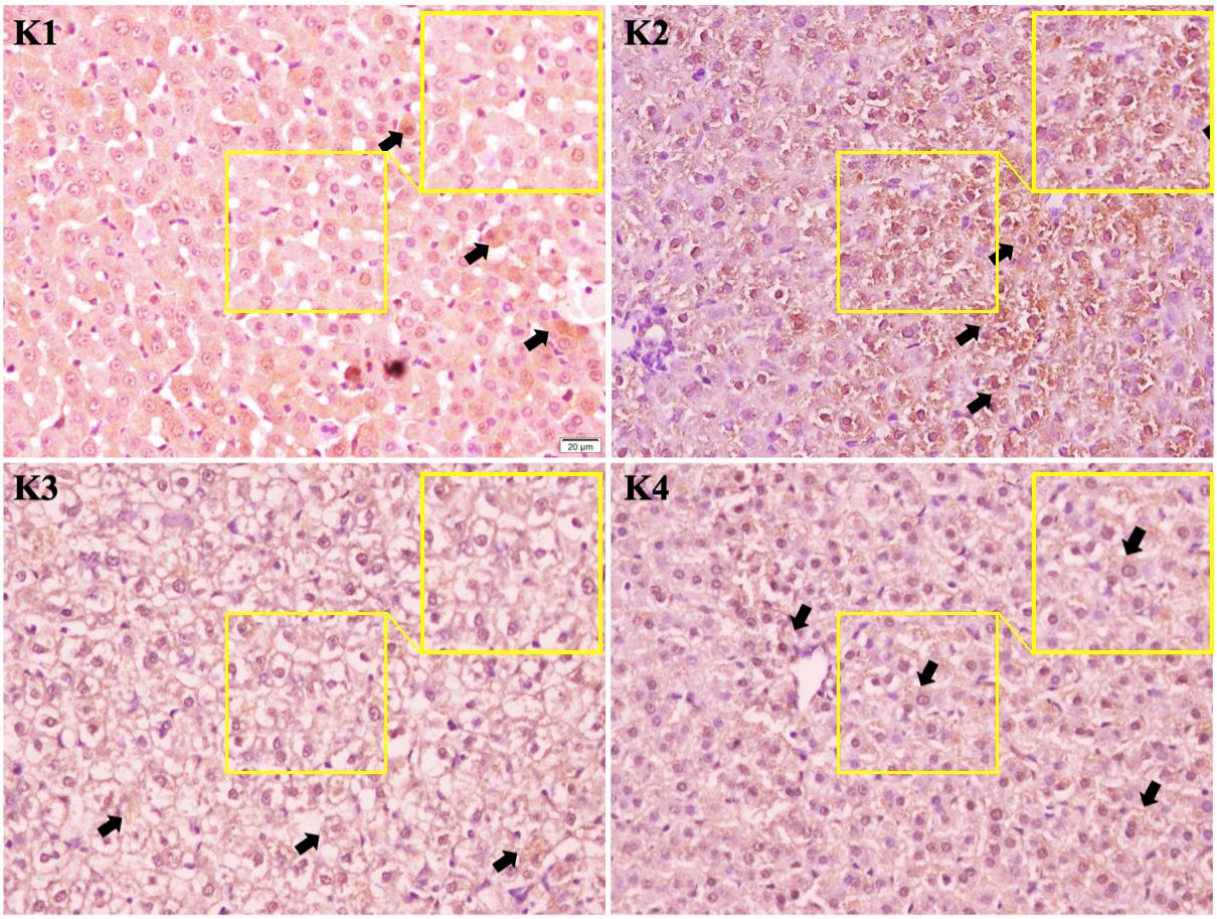

Figure 5. IHC staining of TNFα in the liver tissue of pups. Intense brown staining is prominently visible in the cytoplasm and cell membranes of hepatocytes in the K2 group (IUGR control), magnification 400x

Table 1. Post-Hoc Analysis of TNFα Expression in Liver Tissue

Groups	K1	K2	K3	K4
K1				
K2	<0,001*			
K3	<0,001*	<0,001*		
K4	0,037*	<0,001*	<0,001*	

Note: *Significant p-value < 0.05 (Mann-Whitney test)

3.3. Histopathological Features of Liver Tissue

The meltpeak formed indicated the specificity of the miRNA target (Figure 3). A miRNA target had 1 peak on the meltpeak curve. When there were 2 miRNA targets, 2 different peaks were formed. The peak shift on a miRNA target was influenced by cDNA dilution (1:20 and 1:60). The miRNA quantification process required a total RNA concentration with high yield and purity for cDNA synthesis. In addition, cDNA dilution was also needed for miRNA expression quantification. A good concentration for cDNA synthesis based on the procedure manual of the miRCURY LNA RT kit was 10 ng, so in this study, concentration optimization will be carried out at concentrations of 10, 50, and 100 ng. This was carried out because the amount of miRNA in exosomes was very small, to avoid too low expression, the right concentration was required.

Recent advances continue to support using the NAS for quantifying liver injury. Studies involving animals show that the progression of ballooning, steatosis, and lobular inflammation in rodent models of NAFLD closely resembles that seen in humans, thus underscoring the translational relevance of the scoring method (42). Furthermore, reviews focusing on immunomodulation in the context of NAFLD point to the mechanisms—namely cytokine dysregulation and activation of immune cells—that lead to the various features of NAS (43). Moreover, new molecular insights into inflammatory mediators such as Lipocalin-2 connect the histopathological changes, including hepatocyte ballooning and inflammation, to disease progression and to the interpretation of the score (44). The results showed that the pups in the normal control group had normal liver histology and only very slight signs of inflammation or degeneration. This is in keeping with the standard diet given to this group and therefore suggests that a balanced diet helps to maintain good liver health. On the other hand, the pups in the IUGR control group which underwent a 50% reduction in diet had a marked infiltration of inflammatory cells and hepatocellular degeneration in all areas, especially in the centrilobular zone. These findings indicate that IUGR induced by dietary restriction does cause severe liver damage. This is in agreement with earlier studies which have shown that IUGR is linked to higher levels of oxidative stress and inflammatory responses that lead to damage of liver tissue (1,6,32). The current results therefore support and build upon previous evidence by demonstrating similar histopathological changes in the liver tissue of the IUGR model used in this study.

The pups in the group with IUGR that were given a saffron extract showed signs of inflammation and bleeding in the periportal area, together with degeneration of the hepatocytes in the intermediate and centrilobular regions. Even though its outcome was less favorable than that of the normal control group, saffron supplementation still exhibited a significant protective effect against the hepatic injury caused by IUGR. Saffron includes bioactive substances such as safranal, crocetin, and crocin, which have antioxidant and anti-inflammatory properties and thus reduce oxidative stress and inflammation in the liver tissue (16,17). The pups in the IUGR group that were supplemented with folic acid had almost normal hepatocyte structure with only a minimal amount of inflammatory cell infiltration. This indicates that folic acid has a greater protective effect than saffron. Since folic acid is important in DNA methylation and in the regulation of gene expression, it may help to reduce inflammation by suppressing the expression of TNFα. These results show that folic acid lessens hepatic injury by means of epigenetic mechanisms and increases the cells' resistance to damage (11,33).

Based on Table 2 below, the histopathological evaluation of liver tissue was conducted using the NAS, which includes four scoring parameters: 1) Steatosis, 2) Hepatocyte Ballooning, 3) Lobular Inflammation, and 4) Total NAS (42–44). The data shown in Table 3 indicate that the K2 group had the most severe pathological changes in all the parameters examined, thus showing the greatest severity of NAFLD. The mean scores for steatosis, hepatocyte ballooning and lobular inflammation in the K2 group were 1.98 ± 0.02, 1.96 ± 0.02 and 1.63 ± 0.10, respectively. On the other hand, the K1 group (which served as the normal control) displayed only slight changes, with very low values for all the variables (steatosis: 0.10 ± 0.03, hepatocyte ballooning: 0.96 ± 0.02, lobular inflammation: 0.26 ± 0.05), meaning that it had the least or no signs of NAFLD. The K3 group showed moderate alterations in all the histopathological parameters (steatosis: 1.33 ± 0.06, hepatocyte ballooning: 1.41 ± 0.06, lobular inflammation: 1.46 ± 0.09), indicating an intermediate level of NAFLD severity. The K4 group had values similar to those of the K1 group for both steatosis and hepatocyte ballooning but had a higher score for lobular inflammation (steatosis: 0.01 ± 0.01, hepatocyte ballooning: 0.96 ± 0.02, lobular inflammation: 1.27 ± 0.09). These differences show that the dietary restriction led to varying degrees of liver tissue damage.

Table 3 demonstrates that the K2 group had the highest mean NAS (5.56 ± 0.11), indicating the most severe degree of NAFLD. Conversely, the K1 group recorded the lowest mean NAS (1.36 ± 0.06), representing the mildest condition. The K3 and K4 groups exhibited intermediate NAS values, with K3 (4.20 ± 0.12) and K4 (2.29 ± 0.09) both higher than K1 but lower than K2. The Shapiro-Wilk test for normality showed that all variables deviated from a normal distribution ($p < 0.001$), which required the application of non-parametric statistical tests. The Kruskal-Wallis test identified statistically significant differences among the groups for all measured parameters ($p < 0.001$), including steatosis, hepatocyte ballooning, lobular inflammation, and total NAS. These results confirm significant variation in NAFLD severity across the treatment groups, as depicted in Figure 6. The Mann-Whitney post-hoc test results, presented in Table 4, provide pairwise comparisons among the four groups (K1, K2, K3, K4) for each histopathological parameter: steatosis (ST), hepatocyte ballooning (HB), lobular inflammation (LI), and total NAFLD Activity Score (NAS).

The post-hoc Mann-Whitney test showed significant differences in steatosis (ST), hepatocyte ballooning (HB), lobular inflammation (LI), and the NAFLD Activity Score (NAS) among the groups. The K1 group was significantly different from K2, K3, and K4 for most variables ($p < 0.001$), except for HB when compared with K4 ($p = 0.868$), which was not significant. The K2 group was significantly different from K3 in HB, LI, and NAS ($p < 0.001$), but not in ST ($p = 0.113$). K2 also showed significant differences with K4 in all variables ($p < 0.001$ for HB, LI, and NAS; $p = 0.003$ for ST). K3 and K4 were significantly different in HB, LI, and NAS ($p < 0.001$), but not in ST ($p = 0.115$). These results show that each group had a different level of NAFLD severity, as seen in the significant differences in liver histopathology across all treatment groups.

Statistical analysis found significant differences between the treatment groups in steatosis, hepatocyte ballooning, lobular inflammation, and total NAS. The control group in the IUGR study (K2) had the most severe liver damage, which suggests that dietary restriction causes serious liver injury. Giving saffron and folic acid helped reduce the negative effects of IUGR by improving liver histopathology through different protective actions.

Table 2. NAFLD activity score of liver tissue

Variables	Criteria	Score
Steatosis	<5 %	0
	5 – 33 %	1
	34 – 66 %	2
	>67 %	3
Hepatocyte ballooning	None	0
	Few (< 34 %)	1
	Many (≥ 34 %)	2
Lobular inflammation	None	0
	< 2 foci / Field of view	1
	2 – 4 foci / Field of view	2
	> 4 foci / Field of view	3
	***NAFLD Activity Score* (NAS)**	**0 – 8**

Table 3. Quantitative analysis of liver tissue histopathology

G	Mean + SE				SW	KW
	ST	HB	LI	NAS	p-value	p-value
K1	0,10 ± 0,03[a]	0,96 ± 0,02[a]	0,26 ± 0,05[a]	1,36 ± 0,06[a]	<0,001*	<0,001**
K2	1,98 ± 0,02[ab]	1,96 ± 0,02[ab]	1,63 ± 0,10[ab]	5,56 ± 0,11[ab]		
K3	1,33 ± 0,06[a]	1,41 ± 0,06[abc]	1,46 ± 0,09[abc]	4,20 ± 0,12[abc]		
K4	0,01 ± 0,01[ab]	0,96 ± 0,02[bc]	1,27 ± 0,09[bc]	2,29 ± 0,09[abc]		

Note: G: Groups, ST: steatosis, HB: hepatocyte ballooning, LI: lobular inflammation, NAS: total NAFLD Activity Score, SW: Shapiro-Wilk, KW: Kruskal-Wallis. *Significant at $p < 0.05$ (Shapiro-Wilk test: data not normally distributed). **Significant at $p < 0.05$ (Kruskal-Wallis test). [a,b,c]Significant differences between groups in Table 4 (Mann-Whitney post-hoc test)

3.4. Mechanistic Considerations: Saffron vs. Folic Acid

Saffron contains bioactive compounds, including crocin, crocetin, and safranal, which possess antioxidant and anti-inflammatory properties. In this study, the effect of saffron was less pronounced than that of folic acid. This difference is likely due to the metabolic processing of saffron constituents. Previous research demonstrates that crocin, the primary water-soluble carotenoid in saffron, is metabolized in the digestive tract to form crocetin, which is absorbed at variable rates and does not accumulate significantly in certain organs. Although absorption efficiency was not evaluated in the current study, these pharmacokinetic factors may explain the moderate hepatoprotective effect observed at the administered dose (15.68 mg/kg) in the IUGR model. Saffron has also been shown to reduce oxidative stress and inflammation, partly by modulating the NF-κB pathway through its antioxidant activity.

These mechanisms may have contributed to the partial reduction in TNF-α expression observed, although the specific molecular pathways were not investigated and should be interpreted cautiously. Future research should include pharmacokinetic studies of saffron and analyses of its effects on molecular pathways to clarify its protective role in the liver.

Folic acid exhibited a more substantial protective effect against hepatic inflammation and histological alterations. This effect is likely attributable to the established role of folate in one-carbon metabolism, which facilitates the production of S-adenosylmethionine (SAM), a critical methyl donor involved in DNA methylation. Previous studies have shown that folate status can influence the regulation of inflammatory genes such as TNF-α and modulate inflammatory signaling pathways. Although epigenetic mechanisms were not directly investigated in this study, these processes may underlie the greater reduction in TNF-α expression observed in the folic acid group. A key strength of this study is the administration of both saffron and folic acid throughout pregnancy and the entire lactation period, providing a more accurate representation of real-world maternal nutrition than studies limited to pregnancy supplementation. These findings enhance understanding of how sustained maternal nutrition affects liver health in offspring exposed to IUGR conditions. Further research incorporating pharmacokinetic analysis and epigenetic profiling is required to validate these proposed mechanisms. TNF-α was selected as the primary inflammatory marker due to its established role in hepatic injury associated with IUGR; however, the inflammatory response involves a complex network of signaling pathways that were not comprehensively examined. Specifically, components of the NF-κB signaling pathway, such as p65 activation, and other pro-inflammatory cytokines like IL-6, were not assessed. Moreover, interactions between inflammatory signaling and oxidative stress pathways may contribute to the hepatic alterations observed in IUGR offspring. Future studies should therefore include more extensive molecular analyses to clarify the mechanisms by which saffron and folic acid influence hepatic inflammation and tissue injury.

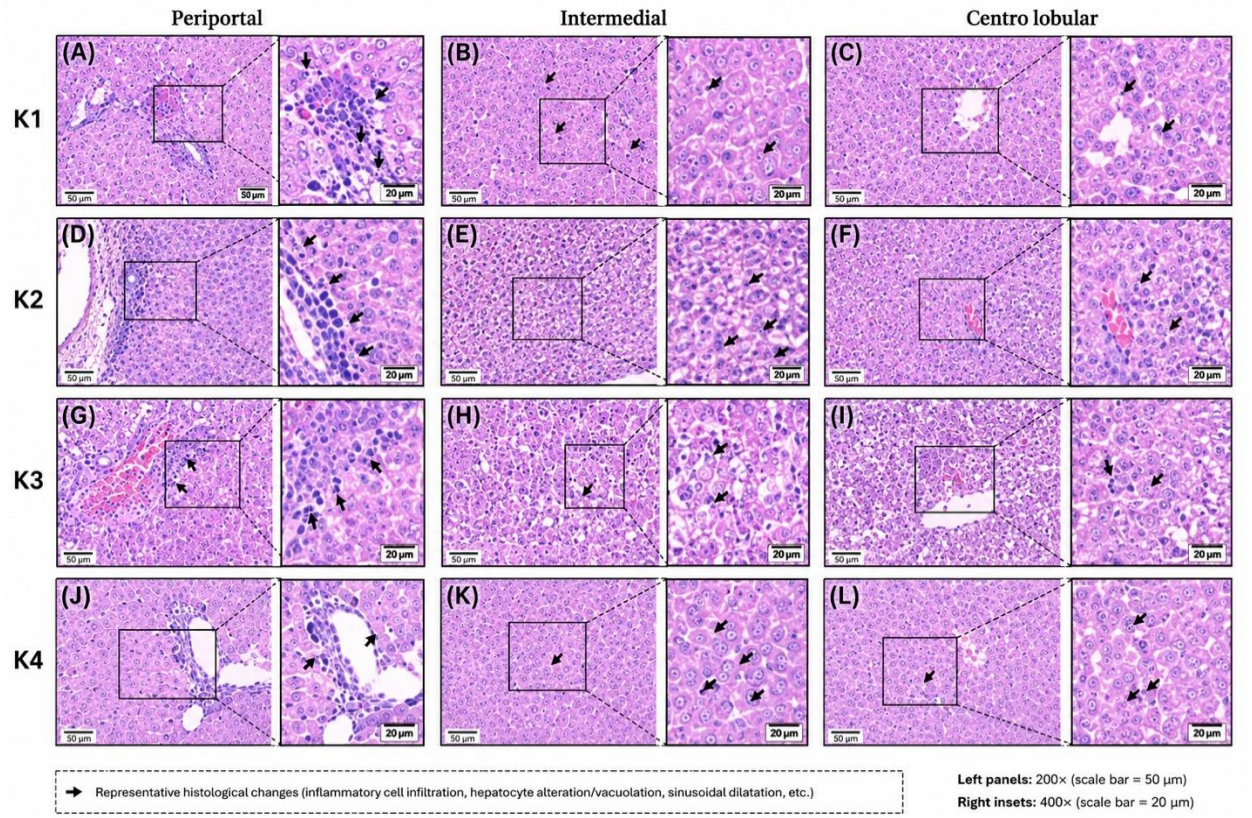

Figure 6. Histopathological comparison of liver tissue across four treatment groups. Hematoxylin and eosin (HE) staining at 400x magnification demonstrates the three zones of the liver lobule: periportal, intermediate, and centrilobular. (A–C) The K1 group (normal control) showed normal hepatocyte architecture without signs of inflammation or degeneration. (D–F) The K2 group (IUGR control) exhibited inflammatory cell infiltration (indicated by arrows) and hepatocellular degeneration in all zones, with the most severe damage observed in the centrilobular zone (F). (G–I) The K3 group (IUGR + Saffron) displayed significant inflammatory infiltration in the periportal zone (G) and severe hepatocyte degeneration in the intermediate and centrilobular zones (H, I). (J–L) The K4 group (IUGR + Folic Acid) showed near-normal hepatocyte architecture with minimal inflammatory infiltration, indicating a protective effect against liver tissue damage

Table 4. Post-hoc analysis of NAFLD Activity Score (NAS) between groups

Group	Comparison	ST (p-value)	HB (p-value)	LI (p-value)	NAS (p-value)
K1	K2	<0,001*	<0,001*	<0,001*	<0,001*
K1	K3	<0,001*	<0,001*	<0,001*	<0,001*
K1	K4	<0,001*	0,868	0,028	<0,001*
K2	K3	0,113	<0,001*	<0,001*	<0,001*
K2	K4	0,003*	<0,001*	<0,001*	<0,001*
K3	K4	0,115	<0,001*	<0,001*	<0,001*

Note: *Significant p-value < 0.05 (Mann-Whitney test)

4. CONCLUSIONS

The study finds that when mothers' diets are restricted it is possible to produce in their offspring an experimental instance of intrauterine growth restriction (IUGR), this being characterized by lower birth weight, higher levels of TNF-α in the liver, and damage to the liver structure. During pregnancy and while lactating, giving the mothers either saffron or folic acid greatly increased the birth weight, lowered the expression of TNF-α in the liver, and improved the histopathological changes in the liver as compared with the untreated IUGR control group. Although both interventions had beneficial effects, folic acid caused greater improvements in the inflammatory markers and in liver structure than saffron. The results show that maternal nutritional supplementation may be of help in reducing the hepatic injury linked with IUGR and point to the possible usefulness of saffron as a complementary nutritional intervention. However, since the underlying molecular mechanisms were not directly investigated and the findings are based on an animal model, further molecular and translational studies should be carried out to confirm these effects and to evaluate their clinical relevance.

Author contributions: NAH, VPK: Conceptualization, methodology, validation, resources, data curation, funding acquisition. NAH, VPK, JS: software. NAH, VPK, IE, LP, JS, MM: formal analysis, writing—original draft preparation, writing—review and editing, visualization, supervision. NAH, VPK: project administration. All authors have read and agreed to the published version of the manuscript.

Funding: This research was funded by the Muhammadiyah University of Sidoarjo as a lecturer scholarship, and the APC was funded by NAH (the author). The funds received were sufficient to conduct this research.

Acknowledgments: None. Contributions from anyone who does not meet the criteria for authorship should be listed, with permission from the contributor, in an Acknowledgments section.

Ethics statement: Our study was approved by the Ethics Committee of the Animal Experiments Local Ethics Committee of Universitas Airlangga (No. 290/EC/KEPK/FKUA/2023).

Conflict of interest: None.

REFERENCES

1. Ariyakumar G, Morris JM, McKelvey KJ, Ashton AW, McCracken SA. NF-κB regulation in maternal immunity during normal and IUGR pregnancies. Sci Rep. 2021;11(1):20971. https://doi.org/10.1038/s41598-021-00430-3
2. Kirici P, Ça FT, Kali Z, Tanriverdi ES, Mavral N, Ecin SM. Determination of maternal serum pro-inflammatory cytokine changes in intrauterine growth restriction. Eur Rev Med Pharmacol Sci. 2023;27(5):1996-2001. https://doi.org/10.26355/eurrev_202303_31565
3. Kalanjati VP, Wixey JA, Miller SM, Colditz PB, Bjorkman ST. GABAA receptor expression and white matter disruption in intrauterine growth restricted piglets. Int J Dev Neurosci. 2017;59:1–9. https://doi.org/10.1016/j.ijdevneu.2017.02.004
4. Shrivastava D, Master A. Fetal growth restriction. J Obstet Gynecol India. 2020;70(2):103–10. https://doi.org/10.1007/s13224-019-01278-4
5. Alese M, Shallie P, Bamisi O. Glutathione improves the prognosis of intrauterine growth restriction via downregulated hepatic and renal TNFα expression in Wistar rats. Cumhuriyet Med J. 2021;43(4):330–8. https://doi.org/10.7197/cmj.860101
6. Keshavjee B, Lambelet V, Coppola H, Viertl D, Prior JO, Kappeler L, Armengaud JB, Chouraqui JP, Chehade H, Vanderriele PE, Allouche M, Balsiger A, Sarre A, Peyter AC, Simeoni U, Yzydorczyk C. Stress-induced premature senescence related to oxidative stress in the developmental programming of nonalcoholic fatty liver disease in a rat model of intrauterine growth restriction. Antioxidants (Basel). 2022;11(9):1695. https://doi.org/10.3390/antiox11091695
7. Armistead B, Kadam L, Drewlo S, Kohan-Ghadr H-R. The role of NFκB in healthy and preeclamptic placenta: trophoblasts in the spotlight. Int Journal of Mol Sci. 2020;21(5):1775. https://doi.org/10.3390/ijms21051775
8. Dapkekar P, Bhalerao A, Kawathalkar A, Vijay N. Risk factors associated with intrauterine growth restriction: A

case-control study. Cureus. 2023;5(6):e40178. https://doi.org/10.7759/cureus.40178

9. Mussa A, Afolabi HA, Syed NH, Talib M, Murtadha AH, Hajissa K, Mokhtar NF, Mohamud R, Hassan R. The NF-κB transcriptional network is a high-dose vitamin C-targetable vulnerability in breast cancer. Biomedicines. 2023;11(4):1060. https://doi.org/10.3390/biomedicines11041060

10. Jiang Z, Qu H, Chen K, Gao Z. Beneficial effects of folic acid on inflammatory markers in the patients with metabolic syndrome: Meta-analysis and meta-regression of data from 511 participants in 10 randomized controlled trials. Crit Rev Food Sci Nutr. 2024;64(16):5450-5461. https://doi.org/10.1080/10408398.2022.2154743

11. Wittiarika ID, Sulistyono A, Prasetyo B, Susanto L, Amalia RB, Dewi ER. Folic acid supplementation in pregnant mice: an approach to reduce the expression of TNF-A and placental apoptosis index in maternal stress. Res J Pharm Technol. 2022;15(8):3645–50. https://doi.org/10.52711/0974-360X.2022.00610

12. Asbaghi O, Ghanavati M, Ashtary-Larky D, Bagheri R, Rezaei Kelishadi M, Nazarian B, Nordvall M, Wong A, Dutheil F, Suzuki K, Alavi Naeini A. Effects of folic acid supplementation on oxidative stress markers: A systematic review and meta-analysis of randomized controlled trials. Antioxidants (Basel). 2021;10(6):871. https://doi.org/10.3390/antiox10060871

13. Zhao M, Chen Y-H, Dong X-T, Zhou J, Chen X, Wang H, Wu S-X, Xia M-Z, Zhang C, Xu D-X. Folic acid protects against lipopolysaccharide-induced preterm delivery and intrauterine growth restriction through its anti-inflammatory effect in mice. PLoS One. 2013;8(12):e82713. https://doi.org/10.1371/journal.pone.0082713

14. Wang CZ, Ma Q, Kim S, Wang DH, Shoyama Y, Yuan CS. Effects of saffron and its active constituent crocin on cancer management: A narrative review. Longhua Chin Med. 2022;5:35. https://doi.org/10.21037/lcm-21-72

15. Vafaeipour Z, Ghasemzadeh Rahbardar M, Hosseinzadeh H. Effect of saffron, black seed, and their main constituents on inflammatory cytokine response (mainly TNF-α) and oxidative stress status: an aspect on pharmacological insights. Naunyn-Schmiedeberg's Arch Pharmacol. 2023;396(10):2241–59. https://doi.org/10.1007/s00210-023-02501-w

16. Afifah MN, Hasanah AN. Saffron (*Crocus sativus* L): Kandungan dan Aktivitas Farmakologinya. Majalah Farmasetika. 2020;5:116–23. https://doi.org/10.24198/mfarmasetika.v5i3.26291

17. Bergomi A, Comite V, Santagostini L, Guglielmi V, Fermo P. Determination of Saffron Quality through a Multi-Analytical Approach. Foods 2022;11(3):3227. https://doi.org/10.3390/foods11203227

18. Rashid M, Brim H, Ashktorab H. Saffron, its active components, and their association with DNA and histone modification: A narrative review of current knowledge. Nutrients. 2022;14(16):3317. https://doi.org/10.3390/nu14163317

19. Kurian K, Lakiang T, Sinha RK, Kathuria N, Krishnan P, Mehra D, Mehra S, Sharma S. Scoping review of intervention strategies for improving coverage and uptake of maternal nutrition services in Southeast Asia. Int J Environ Res Public Health. 2021;18(24):13292. https://doi.org/10.3390/ijerph182413292

20. Abdian S, Fakhri S, Moradi SZ, Khirehgesh MR, Echeverría J. Saffron and its major constituents against neurodegenerative diseases: A mechanistic review. Phytomedicine. 2024;135:156097. https://doi.org/10.1016/j.phymed.2024.156097

21. Ding R, Li J, Zhang Q, Zhang C, Li N, Sun S, Li C, Shen C, Zhao Q, Chen H, Hao J, Cao J. Vitamin D3 protects intrauterine growth restriction induced by cooking oil fume derived fine particulate matters. Ecotoxicol Environ Saf. 2022;229:113103. https://doi.org/10.1016/j.ecoenv.2021.113103

22. The Jackson Laboratory. 6 steps for setting up timed pregnant mice. 2026. https://www.jax.org/news-and-insights/jax-blog/2014/september/six-steps-for-setting-up-timed-pregnant-mice

23. Sreekantha S, Wang Y, Sakurai R, Liu J, Rehan VK. Maternal food restriction-induced intrauterine growth restriction in a rat model leads to sex-specific adipogenic programming. FASEB J. 2020;34(12):16073–85. https://doi.org/10.1096/fj.202000985RR

24. Babaei A, Arshami J, Haghparast A, Danesh Mesgaran M. Effects of saffron (*Crocus sativus*) petal ethanolic extract on hematology, antibody response, and spleen histology in rats. Avicenna J Phytomed. 2014;4(2):103–9. https://pmc.ncbi.nlm.nih.gov/articles/PMC4103705/

25. Nair AB, Jacob S. A simple practice guide for dose conversion between animals and human. J Basic Clin Pharm. 2016;7(2):27–31. https://doi.org/10.4103/0976-0105.177703

26. Kleiner DE, Brunt EM, Van Natta M, Behling C, Contos MJ, Cummings OW, Ferrell LD, Liu YC, Torbenson MS, Unalp-Arida A, Yeh M, McCullough AJ, Sanyal AJ. Nonalcoholic Steatohepatitis Clinical Research Network. Design and validation of a histological scoring system for nonalcoholic fatty liver disease. Hepatology. 2005;41(6):1313-21. https://doi.org/10.1002/hep.20701

27. Konstantopoulos P, Doulamis IP, Tzani A, Korou ML, Agapitos E, Vlachos IS, Pergialiotis V, Verikokos C, Mastorakos G, Katsilambros NL, Perrea DN. Metabolic effects of *Crocus sativus* and protective action against non-alcoholic fatty liver disease in diabetic rats. Biomed Rep. 2017;6(5):513-518. https://doi.org/10.3892/br.2017.884

28. Mashmoul M, Azlan A, Mohtarrudin N, Mohd Yusof BN, Khaza'ai H, Khoo HE, Farzadnia M, Boroushaki MT. Protective effects of saffron extract and crocin supplementation on fatty liver tissue of high-fat diet-induced obese rats. BMC Complement Altern Med. 2016;16(1):401. https://doi.org/10.1186/s12906-016-1381-9

29. Kalanjati VP, Dewi AK, Santoso MWA. Quantitative study on human cerebellar cortex from anatomy cadaver preparations. Int J Morphol. 2017;35(1):167–71. https://doi.org/10.4067/S0717-95022017000100027

30. Schneider CA, Rasband WS, Eliceiri KW. NIH Image to ImageJ: 25 years of image analysis. Nat Methods. 2012;9(7):671–5. https://doi.org/10.1038/nmeth.2089

31. Zhang H, Wang X, Zhang J, Guan Y, Xing Y. Early supplementation of folate and vitamin B12 improves insulin resistance in intrauterine growth retardation rats. Transl Pediatr. 2022;11(4):466-473.. https://doi.org/10.21037/tp-21-498

32. Gao H, Zhang L, Wang L, Liu X, Hou X, Zhao F, Yan H, Wang L. Liver transcriptome profiling and functional analysis of intrauterine growth restriction (IUGR) piglets reveals a genetic correction and sexual-dimorphic gene expression during postnatal development. BMC Genomics. 2020;21(1):701. https://doi.org/10.1186/s12864-020-07094-9

33. Pizzorusso T, Tognini P. Interplay between metabolism, nutrition and epigenetics in shaping brain DNA methylation, neural function and behavior. Genes (Basel). 2020;11(7):742. https://doi.org/10.3390/genes11070742

34. Tzeng H-T, Lee W-C. Impact of Transgenerational nutrition on nonalcoholic fatty liver disease development: Interplay between gut microbiota, epigenetics and immunity. Nutrients. 2024;16(9):1388. https://doi.org/10.3390/nu16091388

35. Esrefoğlu M, Selek S, Koktasoglu F, Bayindir N, Hekimoglu ER, Kirmizikan S, Karakaya-Cimen FB, Dulun-Agac H, Alim M, Elibol B, Pasin O, Bekiroglu S. Unraveling hepatic consequences of intrauterine growth restriction and catch-up growth: insights from histological, biochemical and metabolomic analysis in rats. Int J Dev Biol. 2025;69(1):35-50. https://doi.org/10.1387/ijdb.240147me

36. Bahari H, Shahraki Jazinaki M, Aghakhani L, Amini MR, Noushzadeh Z, Khodashahi R, Malekahmadi M. Crocin supplementation on inflammation and oxidative stress: A Systematic review and meta-analysis. Phytother Res. 2025;39(1):465–79. https://doi.org/10.1002/ptr.8380

37. Zargarzadeh N, Severo JS, Pizarro AB, Persad E, Mousavi SM. The effects of folic acid supplementation on pro-inflammatory mediators: A systematic review and dose-response meta-analysis of randomized controlled trials. Clin Ther. 2021;43(12):e346–63. https://doi.org/10.1016/j.clinthera.2021.10.002

38. Mohammadi Y, Rezaei Farimani A, Beydokhti H, Riahi SM. Comparison of the effect of saffron, crocin, and safranal on serum levels of oxidants and antioxidants in diabetic rats: A systematic review and meta-analysis of animal studies. Food Sci Nutr. 2023;11(6):2429–39. https://doi.org/10.1002/fsn3.3302

39. Zarate MA, De Dios RK, Balasubramaniyan D, Zheng L, Sherlock LG, Rozance PJ, Wright CJ. The acute hepatic Nf-κB-mediated proinflammatory response to endotoxemia is attenuated in intrauterine growth-restricted newborn mice. Front Immunol. 2021;12:706774. https://doi.org/10.3389/fimmu.2021.706774

40. Ponsuksili S, Murani E, Hadlich F, Iqbal MA, Fuchs B, Galuska CE, Perdomo-Sabogal A, Sarais F, Trakooljul N, Reyer H, Oster M, Wimmers K. Prenatal transcript levels and metabolomics analyses reveal metabolic changes associated with intrauterine growth restriction and sex. Open Biol. 2022;12(9):220151. https://doi.org/10.1098/rsob.220151

41. Zhao Y, Xiong W, Li C, Zhao R, Lu H, Song S, Zhou Y, Hu Y, Shi B, Ge J. Hypoxia-induced signaling in the cardiovascular system: pathogenesis and therapeutic targets. Sig Transduct Target Ther. 2023;8(1):1–42. https://doi.org/10.1038/s41392-023-01652-9

42. Fang T, Wang H, Pan X, Little PJ, Xu S, Weng J. Mouse models of nonalcoholic fatty liver disease (NAFLD): pathomechanisms and pharmacotherapies. Int J Biol Sci. 2022;18(15):5681–97. https://doi.org/10.7150/ijbs.65044

43. Guo Z, Wu Q, Xie P, Wang J, Lv W. Immunomodulation in non-alcoholic fatty liver disease: exploring mechanisms and applications. Front Immunol. 2024;15:1336493. https://doi.org/10.3389/fimmu.2024.1336493

44. Wang X, Jin X, Li H, Zhang X, Chen X, Lu K, Chu C. Effects of various interventions on non-alcoholic fatty liver disease (NAFLD): A systematic review and network meta-analysis. Front Pharmacol. 2023;14:1180016. https://doi.org/10.3389/fphar.2023.1180016