









## RESEARCH ARTICLE

# Expression of gonadotropin-releasing hormone receptor type-II correlates with proliferation activity in tissue microarray of rare ovarian tumor

Kiky Martha Ariesaka <sup>1,2</sup>, Ardhanu Kusumanto <sup>3</sup>, Muhammad Ary Zucha <sup>3</sup>,

Nungki Anggorowati <sup>4</sup>, Agil Wahyu Wicaksono <sup>5</sup>, Moch Yunus <sup>6</sup>,

Erianto Fanani <sup>7</sup>, Moh Mirza Nuryady <sup>8</sup>

<sup>1</sup>Department of Parasitology, Faculty of Medicine, Universitas Negeri Malang, Malang, Indonesia

<sup>2</sup>Master program in Biomedical Science, Faculty of Medicine, Public Health and Nursing, Universitas Gadjah Mada, Yogyakarta, Indonesia

<sup>3</sup>Department of Obstetrics and Gynecology, Faculty of Medicine, Public Health and Nursing, Universitas Gadjah Mada, Yogyakarta, Indonesia

<sup>4</sup>Department of Anatomical Pathology, Faculty of Medicine, Public Health, and Nursing, Universitas Gadjah Mada, Yogyakarta, Indonesia

<sup>5</sup>Faculty of Medicine, IPB University, Bogor, Indonesia

<sup>6</sup>Department of Physiology, Faculty of Medicine, Universitas Negeri Malang, Malang, Indonesia

<sup>7</sup>Department of Public Health, Faculty of Medicine, Universitas Negeri Malang, Malang, East Java, Indonesia

<sup>8</sup>Biology Education Study Program, Faculty of Teacher Training and Education, Universitas Muhammadiyah Malang, Malang, East Java, Indonesia

## Correspondence:

Kiky Martha Ariesaka  
Semarang street No. 5 Malang, Malang –  
65145, East Java, Indonesia

Email: [kiky.martha.fk@um.ac.id](mailto:kiky.martha.fk@um.ac.id)

## Article history:

Received: 2024-06-10

Revised: 2024-08-05

Accepted: 2024-08-05

Available online: 2024-10-25

## Keywords:

Proliferative activity

GnRHR-II

Ki67

Rare ovarian tumor

TMA

<https://doi.org/10.33086/ijmlst.v6i2.6034>



## Abstract

Activation of Gonadotropin-Releasing Hormone type II Receptors (GnRHR-II) exhibits antiproliferative activity. GnRHR-II is not only expressed exclusively in the pituitary, but also in a variety of tumors. To date, the clinical relevance of GnRHR-II in ovarian tumors is unclear. In addition, there is a lack of literature addressing GnRHR-II in ovarian tumors, especially rare types. This study was conducted to investigate the correlation between GnRHR-II expression with clinicopathology and proliferative activity of rare ovarian tumors. The purpose of this study was an analytic observational study with a cross-sectional design that utilized 18 ovarian tumor samples on tissue microarray (TMA). The expression of GnRHR-II and Ki67 was assessed using immunohistochemical staining (IHC) and observed using the IHC profiler plugin ImageJ software to obtain their respective H-scores. The data was analyzed using independent t-test, ANOVA, Pearson's test, and Fisher's exact test based on data types. The value of  $p < 0.05$  was considered statistically significant. GnRHR-II is expressed in various forms in ovarian tumors, including extrapituitary expression. GnRHR-II expression was highest in the sex cord stromal tumor (SCST) group,  $110.30 \pm 23.89$  ( $p < 0.0001$ ). In addition, there was also a significant difference between GnRHR-II expression with age ( $p < 0.001$ ) and the primary tumor ( $p < 0.05$ ), but not with tumor type ( $p = 0.101$ ). There is a correlation between GnRHR-II expression and proliferative activity ( $r = -0.043$ ,  $p = 0.866$ ). Elevated GnRHR-II expression is significantly correlated with SCST, individuals over 40 years of age, and tumors confined to the ovary and it correlates with lower proliferative activity, although this correlation is very weak.

**Citation:** Ariesaka KM, Kusumanto A, Zucha MA, Anggorowati N, Wicaksono AW, Yunus M, Fanani E, Nuryady MM. Expression of gonadotropin-releasing hormone receptor type-II correlates with proliferation activity in tissue microarray of rare ovarian tumor. *Indones J Med Lab Sci Technol.* 2024;6(2):95–106. <https://doi.org/10.33086/ijmlst.v6i2.6034>



This is an open access article distributed under the [Creative Commons Attribution-ShareAlike 4.0 International License](https://creativecommons.org/licenses/by-sa/4.0/), which permits unrestricted use, distribution, and reproduction in any medium, provided the original work is properly cited. ©2024 The Author(s).

## 1. INTRODUCTION

Rare tumors represent a distinct challenge in clinical practice. Rare tumors are defined as an incidence of less than 6/100,000 persons per year (1). Rare tumors generally have a poorer outcome. This is due to (1) delays in accurate diagnosis (2), less optimal management from limited experience (3), difficulties in developing new therapies because there are too few patients for adequate clinical trials in determining the gold standard regimen of therapy (2,4), and less financial support for research development compared with more prevalent tumors (3).

Rare tumors pose a distinct challenge in clinical practice. They are characterized by an incidence rate of fewer than 6 case per 100,000 persons per year (1). Generally, rare tumors result in poorer outcomes. This is due to delays in accurate diagnosis, less optimal management from limited experience, difficulties in developing new therapies because there are too few patients for adequate clinical trials in determining the gold standard regimen of therapy, and less financial support for research development compared with more prevalent tumors (2).

The term “rare tumor” of the ovary primarily refers to nonepithelial tumor types, such as germ-cell tumor (GCT) and sex-cord stromal tumor (SCST). GCTs are formed from germ cells, specifically embryonic cells that develop into reproductive cells. GCT subtypes include dysgerminoma, teratoma, yolk sac tumor and mixed germ cell tumor (3).

The SCSTs are a heterogeneous group and are formed by a variety of cell types that arise from primitive sex cords or stromal cells. Stromal cells include theca cells, fibroblasts, and Leydig cells while gonadal primitive sex cords include granulosa cells and Sertoli cells (4). In contrast to the more common malignant epithelial ovarian tumors, borderline ovarian tumors represent only 10-20% of epithelial ovarian tumors. These tumors are classified separately due to their different characteristics compared to malignant and benign tumors. This tumor is also rare with an incidence of 1.8-4.8 per 100,000 women per year (5).

Ovarian tumors can be influenced by hormones, one of which is the hypothalamic-pituitary-gonadal axis (HPG axis) (6). Gonadotropin-releasing hormone (GnRH) is a neuropeptide released by the hypothalamus and plays an important role in ovarian function and ovarian tumor development (7). The GnRH receptor (GnRHR) has two isoforms, namely type I and type II. The relatively new type II GnRH receptor is not only exclusively in the pituitary, but also in various peripheral organs, including the central nervous system, reproductive tract, placenta, endometrium and ovarian granulosa cells. Some gynecological malignancies such as ovarian cancer also express GnRHR (8). Activation of this receptor demonstrates strong antitumor activity, including antiproliferative, antiangiogenesis and antimetastatic effects (7).

Cell proliferation plays an important role in the development of ovarian tumors. Ki-67, a marker expressed during all active phases of the cell cycle, is commonly used as a marker of tumor proliferation in various studies (9). Grundker *et al.* (10) demonstrated the antiproliferative effect of GnRH-I or GnRH-II agonists in endometrial cancer cell lines expressing GnRHR-II mRNA. The antiproliferative effect induced by GnRH-II is influenced by time and dose (10). The antiproliferative effects of GnRH-II are significantly greater than those of GnRH-I agonists, however, the signal transduction mechanisms underlying the GnRH-II system are still unknown (10). It is believed that GnRH-II interacts with pathways that regulate the cell cycle, therewith influencing proliferative activity (10).

Immunohistochemical staining is conventionally performed on whole tissue sections from paraffin blocks to evaluate protein expression as a prognostic marker. However, this technique, which requires processing and staining hundreds or even thousands of slides, is very time consuming when studying a large number of tumors or multiple markers (11). Tissue Microarray (TMA) was first introduced in 1998 and represents a new technology for histopathological examinations, including immunohistochemistry (IHC) and fluorescent in-situ hybridization (FISH) (12).

Samples were extracted from formalin-fixed, paraffin-embedded (FFPE) tissue and arranged in a matrix configuration inside recipient paraffin blocks, facilitating the rapid analysis of hundreds of patient samples. With this relatively new technology, numerous specimens can be inserted into a TMA block, which can be then tested by various techniques, including the IHC method. TMA allows for a more efficient, comprehensive, and lower cost of tumor biology assessment compared to conventional methods such as single tissue block (12). Based on the explanation above, the authors are interested in examining the correlation between GnRHR-II expression, proliferative activity and histopathological type in rare ovarian tumors using TMA specimens.

## 2. MATERIALS AND METHODS

### 2.1. Study Design

This study is an analytical observational study with a cross-sectional design to examine the relationship between the expression GnRHR-II with clinicopathological features and proliferative activity of rare ovarian tumors.

### 2.2. Subject

This study utilized samples from commercial Tissue Micro Array (TMA) provided by Novus Bio (US), NBP2-30290 - Human Ovary Tissue MicroArray (Cancer), which consist of 59 human ovarian tumor cores and 1 carbon core as a position marker. Samples were excluded if: 1) Type of ovarian tumor with a prevalence > 6/100,000 people/year; 2) Ovarian tumor type with frequency >10%; 3) Incomplete clinicopathological data; and 4) Core is missing/damaged. This research was conducted following approval from the Ethics Committee of the Faculty of Medicine, Public Health and Nursing at Universitas Gadjah Mada on December 26<sup>th</sup> 2022 (KE/0806/05/2023).

### 2.3. Immunohistochemical Staining

Once deparaffinization and hydration were completed, antigen retrieval was carried out with warming the slides in EDTA buffer (pH 9.0) at 90°C for 20 minutes using the pretreatment module. The slides were then washed with PBS for 15 minutes and added 3% hydrogen peroxide solution for 6 minutes. The slides were washed again with PBS for 15 minutes. Next, the slides were incubated with blocking serum for 30 minutes, followed by incubation with rabbit polyclonal anti-GnRHR2 catalog no. bs-11403R (Bioss, US) and anti-Ki-67 antibodies (catalog no. ab15580) for 60 min each, at a dilution of 1:200 dilution. After washing with PBS for 15 minutes, the slide was incubated with a secondary antibody (Ultratek Anti-polyvalent, Biotinylated) for 30 minutes and washed again with PBS for 15 minutes. In addition, the slides were incubated with HRP for 30 minutes and washed with PBS for 15 minutes. The slides were then incubated in fresh DAB solution for 2 minutes, and the reaction was stopped by washing in tap water. Counterstaining was performed by soaking the slides in Meyer's hematoxylin for 1 minute. The slides were dehydrated through a graded series of ethanol (10 dips at each concentration) and cleared in xylene for 10 dips. Finally, the slides were mounted and covered with glass coverslips.

### 2.4. Assessment of GnRHR-II and Ki67 Expression

Observations were made using a confocal microscope equipped with optilab using a magnification of 400 times. Each core was observed and images were captured from four fields of view. GnRHR-II and Ki67 expression was assessed quantitatively using histochemical score (H-score) (13). The H-score is based on the intensity of staining and the percentage of positively stained cells, with values ranging from 0 to 300 (14). The H-score for the four visual fields was then calculated to determine the average value, using the formula:

$$\text{H-Score} = (0 \times P_0) + (1 \times P_1) + (2 \times P_2) + (3 \times P_3) \dots\dots\dots (1)$$

where P<sub>0</sub>, P<sub>1</sub>, P<sub>2</sub>, and P<sub>3</sub> represent the percentage of cells with staining intensities of 0, 1, 2, and 3, respectively

The entire process of obtaining intensity and cell percentage data was carried out semi-automatically using the IHC Profiler plugin in ImageJ v1.53 software.

### 2.5. Statistical Analysis

Statistical analysis was conducted using SPSS 22.0. The relationship between GnRHR-II expression and clinicopathology variables was analyzed using the independent t-test for two variables and ANOVA for more than two variables). The correlation between GnRHR-II and Ki67 was analyzed using Pearson's test, and their relationship was analyzed using Fisher's exact test. A p-value of less than 0.05 was considered statistically significant.

## 3. RESULTS AND DISCUSSION

GnRH is an important hormone in the hypothalamus-pituitary-gonadal axis, and GnRHR is a G-protein-coupled receptor located trans-membrane (15). GnRH analogues hold potential as ideal candidate for tumor therapy across various types of tumors (16). For example, GnRHR is a highly effective molecular target for the treatment of steroid-dependent prostate cancer by suppressing the pituitary-testicular axis (15). To date, the

clinical relevance of GnRHR in ovarian tumors is unknown. In addition, there is very little literature that discusses GnRHR in ovarian tumors, especially rare types.

GnRH is also known as a regulator of cell proliferation and invasion in a number of malignancies (6). Currently, cytotoxic GnRH agonists have been developed, where cytotoxic substances are covalently bound to GnRH agonists. These cytotoxic GnRH analog specifically binds to the GnRH receptor and its peptide moiety and acts as a chemotherapeutic drug after internalization of the receptor-ligand complex into the cell. Therefore, these cytotoxic GnRH analogues only act on cells that have GnRH receptors on the cell surface, and thus have far fewer side effects than non-conjugated cytotoxic agents (17).

### 3.1. Subject Characteristics

This study used commercial TMA of human ovarian tumors, accompanied by manufacturer's accompanying congenital clinicopathological data. The number of samples analyzed in this study were 18 tumor tissues, with the characteristics of the subjects presented in Table 1. The mean age of the subjects was  $35.17 \pm 18.78$  years. Among the subjects, 27.78% of the subjects were aged less than 21 years, 33.33% of the subjects were between 21 years to 40 years, and the remaining 38.89% are over 40 years old.

The majority of cases were classified as stage IA (72.22%), while the remaining 5.56% were distributed across stages IB, IC, IIB, IIC, and IIIA1. The most primary tumors were found in the T1a category, which was 72.22%. Only one subject had regional lymph node involvement. All subjects did not get distant metastases. More than half of the subjects (72.22%) were included in malignant tumors, and the rest were borderline tumors. As many as 77.78% of the subjects were non-epithelial, and the rest were epithelial. The most common pathological diagnoses included dysgerminoma (22.22%), followed by yolk sac tumor (16.67%), mixed germ cell tumor (5.56%), granulosa cell tumor (22.22%), sertoli-leydig cell tumor (11.11%), papillary serous tumor of borderline malignancy (16.67%) and mucinous cystadenoma of borderline malignancy (5.56%).

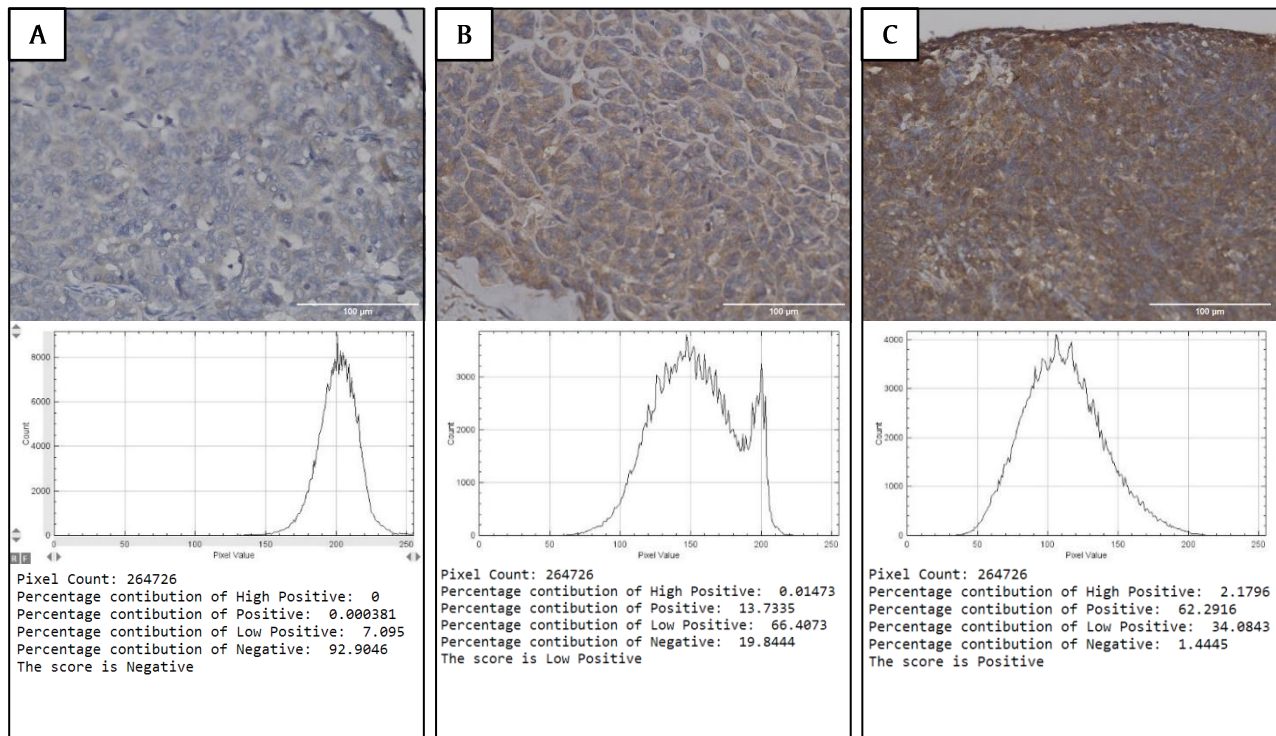
**Table 1.** Subject characteristics

| Parameter                                       | N (%)      | Mean ± SD     |
|---|------------|---------------|
| <b>Age</b>                                      |            | 35.17 ± 18.78 |
| ≤ 20 years                                      | 5 (27.78)  |               |
| 21-40 years                                     | 6 (33.33)  |               |
| > 40 years                                      | 7 (38.89)  |               |
| <b>Stage (AJCC)</b>                             |            |               |
| IE  | 13 (72.22) |               |
| IB  | 1 (5.56)   |               |
| IC  | 1 (5.56)   |               |
| IIB   | 1 (5.56)   |               |
| IIC   | 1 (5.56)   |               |
| IIIA1   | 1 (5.56)   |               |
| <b>Primary tumor</b>                            |            |               |
| T1a   | 13 (72.22) |               |
| T1b   | 2 (11.11)  |               |
| T1c   | 1 (5.56)   |               |
| T2b   | 1 (5.56)   |               |
| T2c   | 1 (5.56)   |               |
| <b>Regional lymph nodes</b>                     |            |               |
| N0  | 17 (94.44) |               |
| N1  | 1 (5.56)   |               |
| <b>Distant metastases</b>                       |            |               |
| M0  | 18 (100)   |               |
| <b>Tumor type</b>                               |            |               |
| Borderline                                      | 5 (27.78)  |               |
| Malignant                                       | 13 (72.22) |               |
| <b>Origin of tumor cells</b>                    |            |               |
| Epithelial                                      | 4 (22.22)  |               |
| Nonepithelial                                   | 14 (77.78) |               |
| <b>Pathology diagnosis</b>                      |            |               |
| Dysgerminoma                                    | 4 (22.22)  |               |
| Yolk sac tumor                                  | 3 (16.67)  |               |
| Mixed germ cell tumors                          | 1 (5.56)   |               |
| Granulosa cell tumor                            | 4 (22.22)  |               |
| Sertoli-leydig cell tumor                       | 2 (11.11)  |               |
| Papillary serous tumor of borderline malignancy | 3 (16.67)  |               |
| Mucinous cystadenoma of borderline malignancy   | 1 (5.56)   |               |



### 3.2. GnRHR-II Expression in Ovarian Tumor TMA

GnRHR-II expression was evaluated using IHC staining, indicated by a positive result when the tumor cytoplasm stained brown from DAB staining. GnRHR-II expression was calculated quantitatively in 4 fields of view using the H-score. In this study, three staining intensities were identified, namely negative (Figure 1A), weak positive (Figure 1B), and positive (Figure 1C). The histogram profile corresponds to the pixel intensity values and the number of pixel intensities. The log below the histogram profile shows the accurate percentage of the pixels present in each pixel intensity zone and their respective scores. The intensity ranges are defines as follows: 61 to 120 pixels for the positive zone; 121 to 180 pixels for the weak positive zone; and 181 to 235 for the negative zone (14).



**Figure 1.** GnRHR-II immunohistochemical staining intensity, histogram profile and score obtained semiautomatically using IHC profiler. The intensity range for the positive zone is from 61 to 120 pixels; 121 to 180 pixels for weak positive zone; and 181 to 235 for the negative zone. (A) Negative with a histogram peak at 200 pixels. (B) Weak positive with a histogram peak at 150 pixels. (C) Positive with a histogram peak at 100 pixels. 400x magnification.

The mean H-score of GnRHR-II in this study was  $78.59 \pm 39.47$ . Most subjects exhibited weak positive staining intensity (55.56%), followed by positive staining (27.78%) and negative staining (16.67%). The staining intensity data are presented in Table 2.

**Table 2.** GnRHR-II staining intensity

|             | Negative<br>N (%) | Weak positive<br>N (%) | Positive<br>N (%) | H-score<br>Mean $\pm$ SD |
|-------------|-------------------|------------------------|-------------------|--------------------------|
| Whole tumor | 3 (16.67)         | 10 (55.56)             | 5 (27.78)         | 78.59 $\pm$ 39.47        |

This study is the first study to examine the expression of GnRHR-II in TMA ovarian tumors, specifically the nonepithelial type. Most of the samples in this study showed weak positive and positive GnRHR-II staining intensity, only 3 samples (16.67%) were GnRHR-II negative. This findings align with previous studies which show that GnRHR is not exclusively expressed by the pituitary, but also in several types of cancer such as ovarian cancer (6), breast cancer (18), prostate cancer (7), gastric cancer (19), and retinoblastoma (20).

### 3.3. Correlation of GnRHR-II expression with clinicopathology

This study analyzed the relationship between the GnRHR-II H-score and various clinicopathological parameters, including histopathological type, age, primary tumor, and tumor type. The results of the analysis are summarized in [Table 3](#).

**Table 3.** GnRHR-II expression based on clinicopathology

| Parameter  | N (%)      | H-score<br>Mean $\pm$ SD | P value      |
|--|------------|--------------------------|--------------|
| <b>Histopathological type (WHO 5<sup>th</sup> ed)</b>  |            |                          | 0.00001 **** |
| GCT  | 8 (44.44)  | 42.52 $\pm$ 11.09        |              |
| SCST   | 6 (33.33)  | 110.30 $\pm$ 23.89       |              |
| BOT  | 4 (22.22)  | 103.15 $\pm$ 36.11       |              |
| <b>Age</b>   |            |                          | 0.00075 ***  |
| $\leq$ 20 years  | 5 (27.78)  | 44.01 $\pm$ 12.57        |              |
| 21-40 years  | 6 (33.33)  | 65.00 $\pm$ 34.31        |              |
| > 40 years   | 7 (38.89)  | 114.93 $\pm$ 24.61       |              |
| <b>Primary tumor</b>   |            |                          | 0.030 *      |
| Limited to the ovaries   | 15 (83.33) | 86.53 $\pm$ 38.36        |              |
| Extension to the pelvis or limited to the ovary with:<br>capsule rupture, tumor on ovarian surface, or malignant<br>cells in ascites or peritoneal | 3 (16.67)  | 38.85 $\pm$ 9.94         |              |
| <b>Tumor type</b>  |            |                          | 0.101        |
| Borderline   | 5 (27.78)  | 136.79 $\pm$ 75.35       |              |
| Malignant  | 13 (72.22) | 124.84 $\pm$ 40.03       |              |

\*p<0.05; \*\*p<0.01; \*\*\*p<0.001 \*\*\*\*p<0.0001

The mean H-scores for the GCT, SCST, and BOT groups were 42.52  $\pm$  11.09, 110.30  $\pm$  23.89, and 103.15  $\pm$  36.11, respectively. The results of the analysis showed that there was a significant difference in the mean H-score based on the histopathological type (p<0.0001). Significant differences were observed between the GCT and SCST groups (p<0.0001) and the GCT and BOT groups (p<0.001).

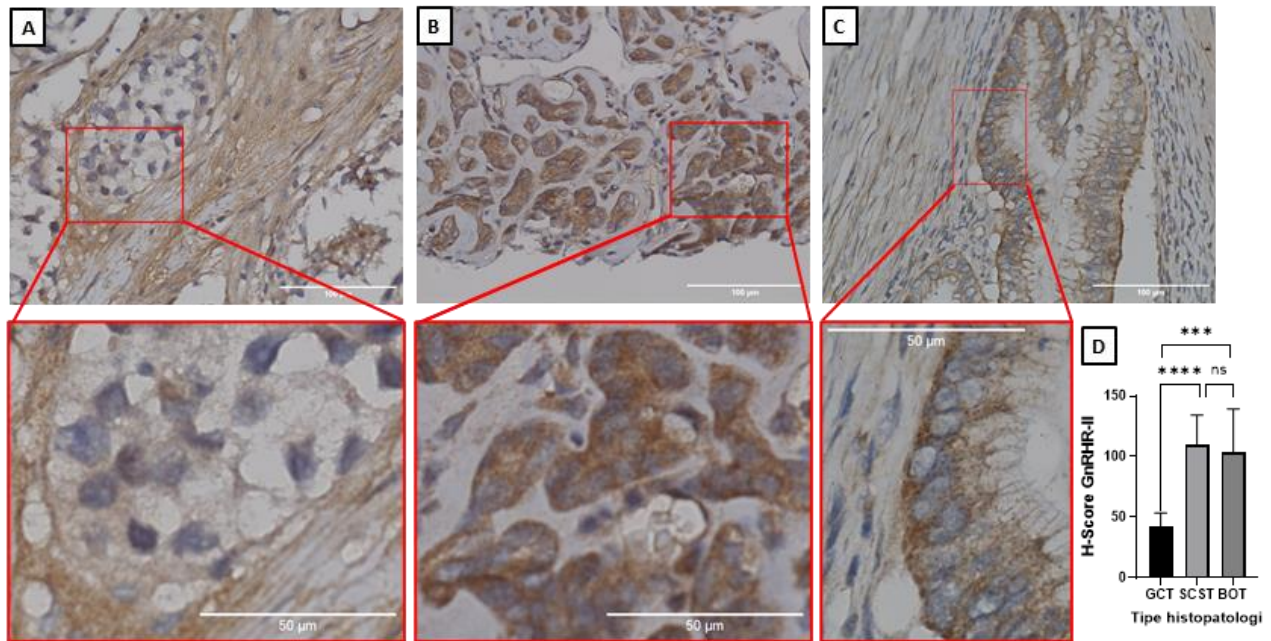
[Figure 2](#) illustrates the expression of GnRHR-II across different histopathological types. The brown staining in the cytoplasm indicates GnRHR-II expression, with notable differences observed between the groups. In panel A, dysgerminoma from the GCT category shows lower staining intensity compared to panel B, which displays a granulosa cell tumor from the SCST category. Panel C shows a mucinous cystadenoma of borderline malignancy from the BOT category. The regions of interest (ROI), marked by the red boxes, were selected by an experienced pathologist for consistent analysis.

Additionally, as shown in [Figure 2D](#), the quantitative analysis of GnRHR-II expression highlights significant differences between the groups. The SCST and BOT categories show much higher GnRHR-II expression compared to the GCT category (p<0.0001 and p<0.001, respectively), consistent with the H-score findings. This visual representation reinforces the statistical significance of GnRHR-II expression differences across the various tumor types.

In this study, we found significant differences in GnRHR-II expression based on histopathological type (p<0.0001), with the highest GnRHR-II expression in the SCST group (granulosa cell tumor and sertoli-leydig cell tumor) which was 110.30  $\pm$  23.89. Given the antitumor potential of GnRHR-II, this research can become the basis for the development of targeted therapy with cytotoxic GnRH analogues, especially in SCST types (granulosa cell tumor and sertoli-leydig cell tumor) which express the highest GnRHR-II.

The mean H-scores for the age group  $\leq$ 20 years, 21-40 years, and > 40 years were 44.01  $\pm$  12.57, 65.00  $\pm$  34.3, and 114.93  $\pm$  24.61, respectively. The analysis revealed significant differences in H-scores based on age group (p<0.001) ([Figure 3A](#)). R mean age of the subjects was 35.17  $\pm$  18.78 years, more than half of the subjects aged  $\leq$ 40 years (61.11%). This finding aligns with previous research which stated that 85% of dysgerminoma patients were diagnosed at the age of less than 30 years. Yolk sac tumors are generally in the age range of 20-30 years (21), sertoli-leydig cell tumor at the age of 20-40 years (22), borderline ovarian tumor in 20-30 years old (22). Granulosa cell tumors have a bimodal age distribution but peak incidence is in the postmenopausal period with a median age of diagnosis of 50-55 years. Granulosa cell tumor of the adult is the most common form, comprising about 95% of cases Most occur at an early stage, in an indolent manner. Juvenile granulosa cell tumors account for a very small

proportion (about 5%), but in prepubertal patients and in women less than 30 years of age, juvenile granulosa cell tumors account for about 90% of cases.



**Figure 2.** GnRHR-II expression. (A) dysgerminoma from the GCT category, (B) granulosa cell tumor from the SCST category (C) mucinous cystadenoma of borderline malignancy from the BOT category. GnRHR-II expression is indicated by brown staining of the cytoplasm. The size of the region of interest (ROI) indicated by the red box was determined by an experienced pathologist. (D) Analysis of GnRHR-II expression by histopathological type. 400x magnification. (ns=not significant; \*\*\* $p < 0.001$ ; \*\*\*\* $p < 0.0001$ ).

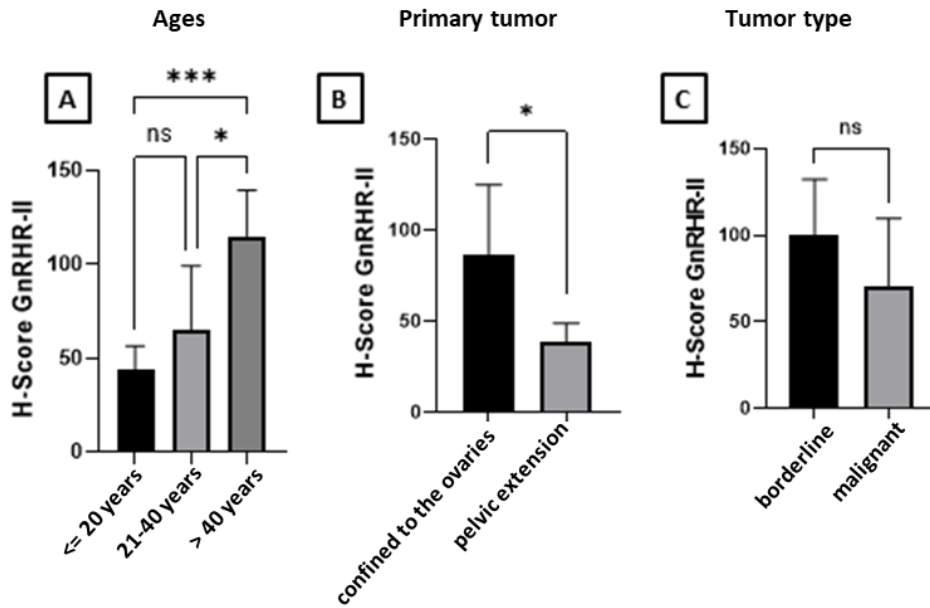
In addition, our study found that GnRHR-II expression tended to be higher in older age groups. This is consistent with research conducted by Zucha *et al.* (8) which reported GnRHR-II expression levels of 45.21 in patients aged  $\leq 35$  years compared to 66.67 in those aged  $> 35$  years. However, this result differs with findings by Walkiewicz *et al.* (23), who observed a decrease in GnRHR mRNA expression in Peripheral Blood Mononuclear Cells (PBMC) from older individuals compared to younger ages. This discrepancy may arise from the heterogeneous nature of the sample, which include various types of ovarian tumors with differing characteristics. In addition, the limited sample size restricted our ability to conduct a thorough age-based analysis of tumor types. Thus, further research is necessary to confirm the relationship between GnRHR-II expression and patient age using a larger and more homogeneous sample.

In this study, the size and location of the primary tumor were classified according to AJCC7 into tumor confined to the ovary (T1a and T1b) and tumor extension to the pelvis or tumor confined to the ovary with one of the following: capsule rupture, tumor on ovarian surface, presence of ovarian cells malignancy in ascites or peritoneal washings (T1c, T2a, T2b, T2c). The mean H-score for tumors confined to the ovary and tumors that extended to the pelvis were  $86.53 \pm 38.36$  and  $38.85 \pm 9.94$ , respectively. The results of the analysis showed that there were significant differences in the H-score based on the primary tumor group ( $p < 0.05$ ) (Figure 3B).

In this study, only two types of tumors were identified, namely borderline and malignant. The mean H-scores for the borderline and malignant groups were  $136.79 \pm 75.35$  and  $124.84 \pm 40.03$ , respectively. However, the analysis showed no significant difference in H-score based on tumor type of ( $p > 0.05$ ) (Figure 3C).

Borderline tumors showed higher expression of GnRHR-II than malignant tumors, but this difference was not statistically significant ( $p = 0.101$ ). The results of this study are in line with similar studies by Lu *et al.* (19) performed on gastric cancer, lower GnRHR expression is associated with a worse prognosis in gastric cancer. Borderline tumors are a type of tumor with low malignant potential that is usually associated with a better prognosis than cancer (24). These findings support that increased expression of GnRHR-II in tumors may benefit ovarian tumors through antitumor activity activated by GnRH binding to its receptor.

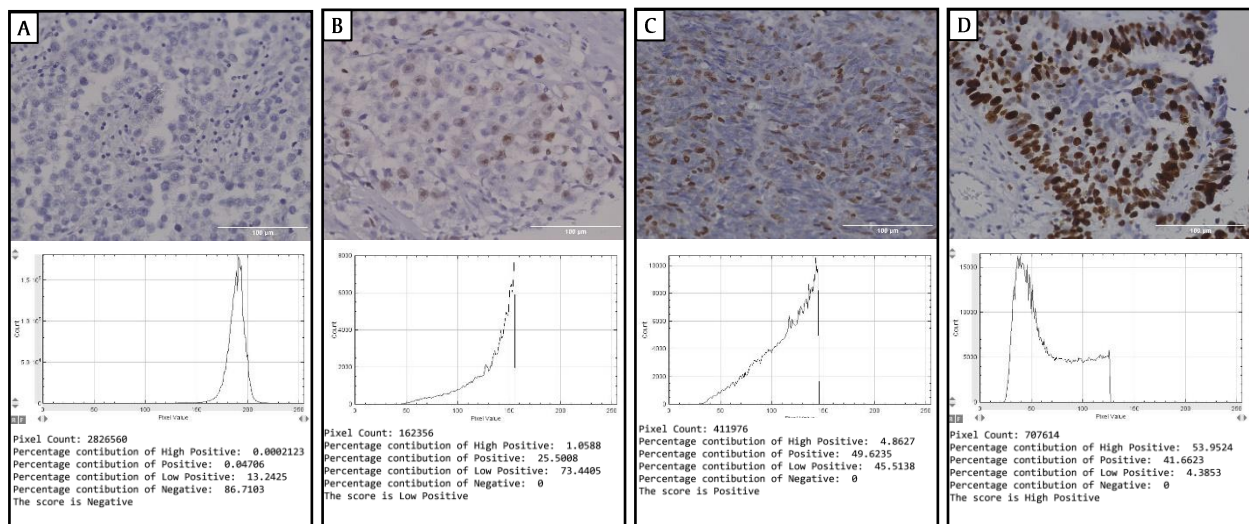




**Figure 3.** GnRHR-II H-score analysis based on clinicopathology. (A) based on age. (B) primary tumor. (C) tumor type (ns = not significant, \*p<0.05, \*\*\*p<0.001)

### 3.4. Expression of Ki67 in Ovarian Tumor TMA

Ki67 expression was evaluated using IHC staining, indicating by a positive result when the tumor nucleus stained brown due to DAB staining. GnRHR-II expression was calculated quantitatively in 4 fields of view using the H-score. In this study, 4 staining intensities were obtained, namely negative (Figure 4A), weak positive (Figure 4B), positive (Figure 4C) and strong positive (Figure 4D). The histogram profile corresponds to the pixel intensity values and the number of pixel intensities. The log below the histogram profile shows the accurate percentage of the pixels present in each pixel intensity zone and their respective scores. The intensity range are defined as follows: strong positive (0 to 60 pixels); positive (61 to 120 pixels); weak positive (121 to 180 pixels); and negative (181 to 235 pixels) (14).



**Figure 4.** Ki67 immunohistochemical staining intensity, histogram profile and score were obtained semiautomatically using IHC profiler. Intensity range for strong positive zone from 0 to 60 pixels, 61 to 120 pixels for positive zone; 121 to 180 pixels for weak positive zone; and 181 to 235 for the negative zone. (A) Negative with a histogram peak at 190 pixels. (B) Weak positive with a histogram peak at 160 pixels. (C) Positive with a histogram peak at 140 pixels. (D) Strong positive with a histogram peak at 40 pixels. 400x magnification.



The mean H-score for Ki67 in this study was  $78.59 \pm 39.47$ . Most subjects exhibited weak positive staining intensity (55.56%), followed by positive staining (33.33%). Strong positive and negative intensities were observed in 5.56% of the subjects each. The staining intensity data are presented in Table 4.

**Table 4.** Ki67 staining intensity

|             | Negative<br>N (%) | Weak positive<br>N (%) | Positive<br>N (%) | Strong positive<br>N (%) | H-score<br>Mean $\pm$ SD |
|-------------|-------------------|------------------------|-------------------|--------------------------|--------------------------|
| Whole tumor | 1 (5.56)          | 10 (55.56)             | 6 (33.33)         | 1 (5.56)                 | 128.16 $\pm$ 49.97       |

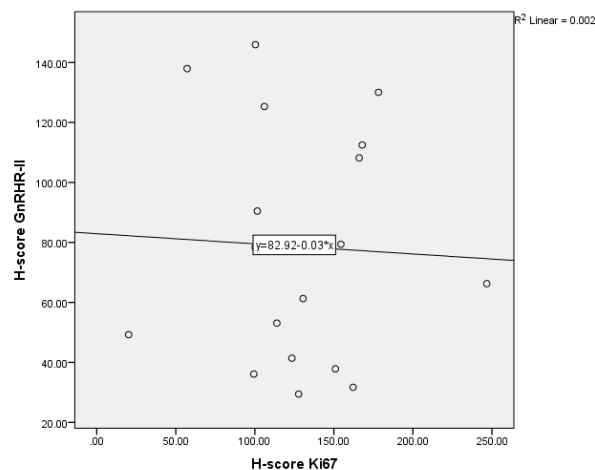
### 3.5. Correlation of GnRHR-II Expression and Proliferative Activity

The correlation coefficient between GnRHR-II and Ki67 was calculated to be -0.043. A correlation coefficient of 0.0 to <0.2 indicates a very weak correlation, and the negative sign indicates the opposite direction of correlation, the greater the value of one variable, the smaller the value of the other variable. The p-value of 0.866 indicates no significant correlation results between the two variables (Table 5).

**Table 5.** Correlation of H- score GnRGR-II and Ki67

| Parameter | H-scores<br>Mean $\pm$ SD | R      | P value |
|-----------|---------------------------|--------|---------|
| GnRHR-II  | 78.59 $\pm$ 39.47         | -0.043 | 0.866   |
| Ki67      | 128.16 $\pm$ 49.97        |        |         |

The direction of the correlation is depicted in the scatter diagram in Figure 5. This study is the first study to examine GnRHR-II expression in rare ovarian tumors, so that the GnRHR-II H-score threshold value can be calculated by the equation obtained, where the Ki67 H-score threshold that causes increased proliferation is >30. With cut-off Ki67 = 30; then the GnRHR-II cut off is as follows:  $y = 82.92 - 0.03x$ . Based on this formula, the threshold for GnRHR-II expression is determined to be 82.02.



**Figure 5.** GnRHR-II and Ki67 H-score correlation scatter diagram

GnRHR-II and Ki67 expression was also categorized into low and high. The results of the analysis showed that there was no significant relationship between the expression levels of GnRHR-II and Ki67 ( $p=1.000$ ) presented in Table 6.

**Table 6.** Correlation of GnRGR-II and Ki67 category

|          |      | Ki67      |            | P value |
|----------|------|-----------|------------|---------|
|          |      | Low       | High       |         |
| GnRHR-II | Low  | 1 (5.56%) | 9 (50.00%) | 1.000   |
|          | High | 0 (0%)    | 8 (44.44%) |         |

This study demonstrated a very weak negative correlation between GnRHR-II and Ki67 expression. In this context, Ki67 serves as a marker of cell proliferation, indicating that the higher the GnRHR-II expression are associated with lower the cell proliferation activity. These findings support previous research that GnRH can provide antiproliferative effects through regulation of the Akt/ERK1/2 pathway and is able to inhibit cell apoptosis in Panc1 cells (pancreatic cancer) (25). The results are consistent with research by Marelli *et al.* (26) which showed that GnRH-II has a specific and significant antiproliferative effect on prostate cancer cells.

Based on the findings, higher expression of GnRHR-II is correlated with lower proliferative activity. However, this relationship exhibits very weak correlation strength and is not statistically significant. The mechanisms and signaling pathways involved are not fully understood in this study. This weak correlation indicates the possibility of a signaling pathway or other mechanism that also influences proliferative activity and intersects with the GnRH-II signaling pathway. Higher expression of GnRHR-II was also significantly associated with tumors confined to the ovary, indicating that GnRHR-II has a role in antiproliferative mechanisms leading to smaller tumor sizes. In addition, GnRHR-II has also been shown to be involved in suppressing malignant transformation in relation to antiproliferative activity. In this study, expression of GnRHR-II in borderline tumors was higher than that of malignant tumors, but these results were not statistically significant, indicating that other signaling pathways were involved, which also affect the malignant transformation of a tumor.

This study has several limitations; 1) It utilized commercial TMA samples originating from the United States, which mean the findings may not be applicable to the general population in Indonesia. Nevertheless, employing TMA is beneficial for preliminary study; 2) The use of commercial TMA is also limited by the scarcity of clinical data provided by the manufacturer; 3) The study employed a semi-automated observation method using software, which introduces the potential for bias, particularly since the software cannot automatically distinguish between normal, tumoral, and stromal tissues. This issues can be addressed by manually selecting the region of interest (ROI) and setting the threshold prior to analysis, which is why the method is described as semi-automatic.

#### 4. CONCLUSIONS

Higher expression of GnRHR-II is significantly correlated with the type of Sex-Cord Stromal Tumor type, individuals over 40 years of age, and tumors that are confined to the ovary. Additionally, it is correlated with lower proliferative activity, although this correlation is very weak.

**Author contributions:** KMA: Conducting research and investigation process, specifically performing the experiments and writing of published work; MAZ: contribute to ideas; provision of GnRHR-II reagent and supervision; NA: contribute to verify IHC output and supervision; AWW: contribute to software analysis of result data; MY: contribute to methodology and financial support for the project leading to this publication; EF: provision of analysis tools and visualization of the published work; MMN: review and editing of the published work; AK: contribute to supervision for the research activity planning and execution.

**Funding:** This work was supported by the Universitas Negeri Malang.

**Acknowledgements:** We gratefully acknowledge the financial support from Universitas Negeri Malang (UM). This grant enabled our research project.

**Ethics statement:** This research is done after get agreement from Committee ethics Faculty of Medicine, Public Health and Nursing Universitas Gadjah Mada on December 26th 2022 (KE/0806/05/2023).

**Conflict of interest:** There is no conflicts of interest to declare.

## REFERENCES

- Wang S, Jiang Y, Miao H, Fang Y, Jiang N, Yu Y, et al. Targeting rare tumors: new focus for clinical research in China. *EMBO Mol Med*. 2023;15(1):e16415. <https://doi.org/10.15252/emmm.202216415>
- Mathoulin-Péllissier S, Pritchard-Jones K. Evidence-based data and rare cancers: The need for a new methodological approach in research and investigation. *Eur J Surg Oncol*. 2019;45(1):22–30. <https://doi.org/10.1016/j.ejso.2018.02.015>
- Pinto MT, Eiras Martins G, Vieira AGS, Galvão JMS, de Pádua Souza C, Macedo CRPD, et al. Molecular biology of pediatric and adult ovarian germ cell tumors: A review. *Cancers (Basel)*. 2023;15(11):2990. <https://doi.org/10.3390/cancers15112990>
- Kaur H, Singh N, Bharti S, Kaur G. Exploring the unusual: a testosterone-secreting ovarian tumor. *Autops Case Reports*. 2024;14:e2024478. <https://doi.org/10.4322%2Facr.2024.478>
- Ozen A, De Berti M, Body G, Carcopino X, Graesslin O, Kerbage Y, et al. Risk factors for recurrence of borderline ovarian tumours after conservative surgery and impact on fertility: a multicentre study by the francogyn group. *J Clin Med*. 2022;11(13):3645. <https://doi.org/10.3390/jcm11133645>
- Gründker C, Emons G. Role of gonadotropin-releasing hormone (GnRH) in ovarian cancer. *Cells*. 2021;10(2):437. <https://doi.org/10.3390%2Fcells10020437>
- Fontana F, Marzagalli M, Montagnani Marelli M, Raimondi M, Moretti RM, Limonta P. Gonadotropin-releasing hormone receptors in prostate cancer: molecular aspects and biological functions. *Int J Mol Sci*. 2020;21(24):9511. <https://doi.org/10.3390/ijms21249511>
- Zucha MA, Dewanto A, Widad S, Taufiqurrachman I, Kusumanto A, Pangastuti N, et al. Expression of GnRH receptor type-ii correlates with proliferation activity in endometriosis. *Int J Infertil Fetal Med*. 2022;13(2):35–9. <https://doi.org/10.5005/jp-journals-10016-1253>
- Dzulkifli FA, Mashor MY. An overview of recent counting methods for Ki67 IHC staining. *J Biomed Clin Sci*. 2018;3(2):10–7. <https://myjurnal.mohe.gov.my/public/article-view.php?id=130450>
- Gründker C, Günther AR, Millar RP, Emons G. Expression of gonadotropin-releasing hormone II (GnRH-II) receptor in human endometrial and ovarian cancer cells and effects of GnRH-II on tumor cell proliferation. *J Clin Endocrinol Metab*. 2002;87(3):1427–30. <https://doi.org/10.1210/jcem.87.3.8437>
- Magaki S, Hojat SA, Wei B, So A, Yong WH. An Introduction to the Performance of Immunohistochemistry. In: *Methods Mol Biol*. 2019. p. 289–98. [https://doi.org/10.1007%2F978-1-4939-8935-5\\_25](https://doi.org/10.1007%2F978-1-4939-8935-5_25)
- Webb F, Morey A, Mahler-Hinder C, Georgousopoulou E, Koo R, Pati N, et al. Comprehensive FISH testing using FFPE tissue microarray of primary lymph node tissue identifies secondary cytogenetic abnormalities in Mantle Cell Lymphoma. *Cancer Genet*. 2023;274–275:75–83. <https://doi.org/10.1016/j.cancergen.2023.04.002>
- Ruengwanichayakun P. Histochemical scoring assessment (H-score). *Asian Arch Pathol*. 2021;13(1):13–4. <https://www.asianarchpath.com/view/152>
- Varghese F, Bukhari AB, Malhotra R, De A. IHC Profiler: an open source plugin for the quantitative evaluation and automated scoring of immunohistochemistry images of human tissue samples. *PLoS One*. 2014;9(5):e96801. <https://doi.org/10.1371/journal.pone.0096801>
- Fanis P, Neocleous V, Papapetrou I, Phylactou LA, Skordis N. Gonadotropin-releasing hormone receptor (GnRHR) and hypogonadotropic hypogonadism. *Int J Mol Sci*. 2023;24(21):15965. <https://doi.org/10.3390/ijms242115965>
- Valsamakis G, Valtetsiotis K, Charmandari E, Lambrinouadaki I, Vlahos NF. GnRH analogues as a Co-treatment to therapy in women of reproductive age with cancer and fertility preservation. *Int J Mol Sci*. 2022;23(4):2287. <https://doi.org/10.3390/ijms23042287>
- Miller DS, Scambia G, Bondarenko I, Westermann AM, Oaknin A, Oza AM, et al. ZoptEC: Phase III randomized controlled study comparing zoptarelin with doxorubicin as second line therapy for locally advanced, recurrent, or metastatic endometrial cancer (NCT01767155). *J Clin Oncol*. 2018;36(15\_suppl):5503–5503. [https://doi.org/10.1200/JCO.2018.36.15\\_suppl.5503](https://doi.org/10.1200/JCO.2018.36.15_suppl.5503)
- Chen C-P, Lu X. Gonadotropin-releasing hormone receptor inhibits triple-negative breast cancer proliferation and metastasis. *J Int Med Res*. 2022;50(3):030006052210828. <https://doi.org/10.1177%2F03000605221082895>
- Lu M, Zhu J, Ling Y, Shi W, Zhang C, Wu H. The lower expression of gonadotropin-releasing hormone receptor associated with poor prognosis in gastric cancer. *Int J Clin Exp Med*. 2015;8(8):13365–70. <https://www.ncbi.nlm.nih.gov/pmc/articles/PMC4612952/>
- Sultan Aldrees PZ. Gonadotropin-Releasing Hormone Receptor is expressed in Retinoblastoma. *J Clin Exp Pathol*. 2015;05(03). <https://iovs.arvojournals.org/article.aspx?articleid=2336405>
- Kaur B. Pathology of malignant ovarian germ cell tumours. *Diagnostic Histopathol*. 2020;26(6):289–97. <https://doi.org/10.1016/j.mpdhp.2020.03.006>
- Boussios S, Moschetta M, Zarkavelis G, Papadaki A, Kefas A, Tatsi K. Ovarian sex-cord stromal tumours and small cell tumours: Pathological, genetic and management aspects. *Crit Rev Oncol Hematol*. 2017;120:43–51. <https://doi.org/10.1016/j.critrevonc.2017.10.007>
- Walkiewicz D, Wicik Z, Puzianowska-Kuznicka M. Gonadotropin-releasing hormone receptor pathway affects the function of human EBV-transformed B lymphocytes in an age-independent way. *Exp Gerontol*. 2021;152:111471. <https://doi.org/10.1016/j.exger.2021.111471>
- Sun Y, Xu J, Jia X. The diagnosis, treatment, prognosis and molecular pathology of borderline ovarian

- tumors: Current status and perspectives. *Cancer Manag Res.* 2020;12:3651–9. <https://doi.org/10.21472/FCMAR.S250394>
25. Suo L, Chang X, Xu N, Ji H. The anti-proliferative activity of GnRH through downregulation of the Akt/ERK pathways in pancreatic cancer. *Front Endocrinol (Lausanne).* 2019;10:370. <https://doi.org/10.3389/fendo.2019.00370>
26. Montagnani Marelli M, Moretti RM, Mai S, Januszkiewicz-Caulier J, Motta M, Limonta P. Type I gonadotropin-releasing hormone receptor mediates the antiproliferative effects of GnRH-II on prostate cancer cells. *J Clin Endocrinol Metab.* 2009;94(5):1761–7. <https://doi.org/10.1210/jc.2008-1741>