



Forensic Examination in Infanticide Case

Hesa Chikita Putrie,^{1*} Safira Mandasari²

¹Forensic Science, Postgraduate School, Airlangga University, Surabaya, Indonesia

²Forensic Science, Postgraduate School, Airlangga University, Surabaya, Indonesia

*Corresponding Author: hesa.chikita.putrie-2022@pasca.unair.ac.id

DOI: 10.33086/iimj.v5i2.5860

ARTICLE INFO

Keywords:

Asphyxia; baby; infanticide; severe neck injury.

Submitted: May 9th 2024

Reviewed: May 27th 2024

Accepted: June 9th 2024

ABSTRACT

Introduction: Infanticide is a crime in which a mother kills her baby during or shortly after birth. In 2020, infanticide cases in Indonesia reached 16.85%. Infanticide is mainly carried out through mechanical asphyxia in the form of smothering and strangulation.

Case: The body of an unidentified female newborn baby was found in the Sandubaya area, Mataram City, on Monday, July 10th 2023. The observation was carried out through external and internal examination of the body.

Discussion: There were bruises and peeling skin all over the body. The autopsy showed a haemorrhage all over the lower part of the scalp, severe injury to the neck, and blood seepage on the right chest.

Conclusions: The cause of death was due to severe neck injury resulting in asphyxia.

Introduction

Infanticide is the killing of one's child by the biological mother to her baby at birth or shortly after birth. The motive for the act is usually triggered by the mother not wanting the baby's birth to be known by others (Atmoko & Niufti, 2023). Data from the Indonesian Central Bureau of Statistics in 2023 states that the three provinces with the highest percentage of homicides are DKI Jakarta (4.12%), Bangka Belitung Islands (2.29%), and West Nusa Tenggara (2.00%). In this study, the author focuses on infanticide cases. In 2020, infanticide cases in Indonesia reached 16.85%, and one of the

provinces with the highest infanticide cases was West Nusa Tenggara Province. In 2020, the infant mortality rate in West Nusa Tenggara (NTB) reached 24.64%, especially in the Mataram city area, reaching 14.46%. In Indonesia, the act of infanticide is regulated in the Indonesian Criminal Code (KUHP) articles 341-342. Some of the factors that encourage infanticide are overwhelming anger due to psychological factors, economic factors, and fear and shame due to the birth of a child from an extramarital relationship.

A baby is born alive if the baby is separated from the mother after birth and

there are signs of life, such as breathing, a beating heart, active movement and crying. There are indicators to say that the baby already has life or is alive, namely, breathing, blood circulation and heartbeat, changes in oxygen levels in the blood, the contents of the digestive tract, the condition of the umbilical cord, and the presence of crying. If at least one of these six characteristics is not present, the baby can be declared lifeless (Amelinda, Hoediyanto, & Kalanjati, 2018). In infanticide cases, death can be unnatural. The mechanism of death in infanticide is physiological mechanisms such as bleeding, asphyxia, or organ damage, and the cause of death could be violence and can have several causes. First, negligence is due to a lack of attention to what should be done for the newborn to survive. Second, due to violence such as birth trauma, blunt force and sharp force. Meanwhile, the cause of death can be due to asphyxia, haemorrhage, hypothermia and dehydration and can not be determined if the body has experienced advanced decomposition (Atmoko & Niufti, 2023). This study aims to describe infant deaths based on external and internal examinations of the Forensic and Medicolegal Installation of Bhayangkara Hospital in Mataram, NTB.

Case

This study was conducted on Wednesday, July 13th 2023, in Bhayangkara

Hospital, Mataram City. This study was an observational descriptive with a case series approach. The observation was carried out through external and internal examination. This study describes an infanticide case of an unidentified female newborn baby that was found in the Sandubaya area of Mataram City on Monday, July 10th, 2023.

Result

The baby girl's body was covered with a brown cardboard box marked "Alia Digital Printex", wrapped in a red plastic bag, a green, black, and yellow floral prayer mat and another red plastic bag, and the body was wrapped in a grey and dark blue sweater, (see Figure 1).



Figure 1. Objects found within the body

An external examination was conducted on Wednesday, July 13th, 2023. The body of a baby girl aged 9 months gestation with a body length of 47 cm and a body weight of 2.05 kg, corpse bruises and skin are peeling all over the body, see Figure 2. Straight black hair with an average length of 3 cm, head circumference 32.5 cm, chest circumference 34 cm, upper arm circumference 11 cm, both eyes are reddish, there is an umbilical cord with a length of 78.5 cm still attached to the placenta

weighing 0.2 kg, the skin of the placenta is decomposed, there are 17 cotyledons, there is body fat (*cervix caseosa*) in the thigh folds.

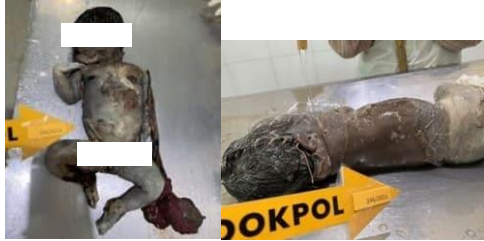

Figure 2. Bruises and skin peeling all over the body

External examination also shows other signs of asphyxia, such as dilation of the eye's blood vessels and blueness of the mucosa of the lips, as in Figure 3. Other external examination results found evidence of suspected strangulation in the neck, as in Figure 4.



Figure 3. Blueness of the mucosa of the lips and dilation of the eye's blood vessels.

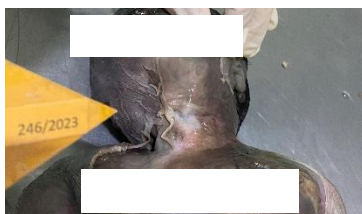


Figure 4. Neck Injuries

Internal examination results are dilation of blood vessels in the brain and a severe head injury that led to bleeding all over the scalp. There was a severe neck injury causing airway obstruction. There was blood infiltration in the right chest Costa 4,

5 and 6 levels, measuring 3.5 cm x 2.5 cm, and dilated veins.

While supporting examination results, the lungs are mosaic. The right lung measures 7 cm x 4 cm x 1.5 cm, and the left measures 5.5 cm x 5 cm x 2 cm. The lung buoyancy test shows both lungs are buoyant; see Figure 5. The heart measures 3.5 cm x 3.5 cm x 1 cm. There are no other tests that are used to find out that the baby was born alive, such as Wreden's test and Bresslau's test, because internal organs such as the intestines, stomach, and others have experienced advanced decay.

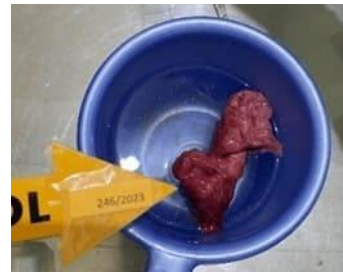

Figure 5. Lung buoyancy test

Discussion

According to the Indonesian Criminal Code (KUHP), murder consists of several types, namely ordinary murder, premeditated murder, murder to commit another crime and infanticide. In the Indonesian Criminal Code (KUHP) infanticide is a murder committed by a mother for fear of being caught giving birth to a baby at the time of birth or shortly after birth, intentionally or unintentionally taking the life of her child listed in the chapter of

crimes against the life of the person articles 341, 342 and 343 (Radja, Saragih, & Henok, 2023; Tantimin, Febriyani, & Putra, 2023). In infanticide cases, several things must be known, namely, evidence that the baby was born alive and there are signs of violence that caused the death (Khoiriah & Pratiwi, 2019; Langer, 1974; Susanti, 2012). There are several indicators that a baby is considered newborn and alive, namely full term or not, gestational age, postnatal age, baby's first nutritional intake, crying, moving limbs, and breathing. One of the early infant deaths is characterized by no visible signs of the mother's initial care for the baby (Atmoko & Niufti, 2023; Shkrum, 2007).

In terms of proving infanticide cases, it can be seen from whether the baby was born alive or dead (Atmoko & Niufti, 2023; Langer, 1974). Based on the results of the examination, there is a mosaic picture in the lungs, and the results of the lung buoyancy test show a positive result, which means that the baby was breathing, so it can be said that in this case, the baby was born alive (Shkrum, 2007). In some cases, it has been shown that if the lungs have a mosaic pattern, the lung buoyancy test is particular to be positive, and it can be concluded that the baby was breathing and was born alive (Afandi, Hertian, Atmadja, & Widjaja, 2008; Atmoko & Niufti, 2023). Mechanical asphyxia accounts for 90-95% of the 30-40

deaths per year (Afandi et al., 2008; Pradhika, 2011).

Mechanical asphyxia is suffocation and strangulation, which can be seen based on the results of external and internal examinations. Suffocation or strangulation is the easiest way for the perpetrator to commit infanticide; asphyxia is done to prevent the baby from crying so that her actions are not known by others (Afandi et al., 2008; Atmoko & Niufti, 2023; Langer, 1974; Oberman, 2001; Tantimin et al., 2023). There were no bruises and abrasions in this case, but the skin was peeling all over. There were corpse bruises all over the body, the eyes were red.

The infant had severe neck injuries, as in Figure 4, suggesting that the infant's neck had been twisted or kicked. The external examination results in Figure 3 there are findings that support signs of asphyxia, such as the blood vessels of the eyes and the blueness of the mucosa of the lips. In addition, there were severe head injuries characterized by haemorrhaging over the entire lower area of the scalp. There were no injuries caused by violence with sharp objects, and no open wounds were found. However, blood was found on the right side of the chest at the level of the fourth, fifth and sixth ribs, indicating signs of blunt force trauma.

Based on external examination, it was determined that the body was a newborn

baby who had not been cared for because there were no signs of care. This conclusion is supported by the fact that the umbilical cord is still attached to the placenta weighing 0.2 kg with a cord length of 78.5 cm, and the cervix caseosa can be seen around the thigh folds. The gestational age was approximately 37-42 weeks or 9-10 months, which results from calculating the Haase formula, where the baby's body length is 47 cm divided by 5. In cases of infanticide, the best estimate of gestational age can be seen by measuring the head circumference (Afandi et al., 2008; Atmoko & Niufti, 2023). The examination of the baby showed that the baby had a head circumference of 32.5 cm, which means that the baby was full term (37-42 weeks).

Babies are said to be able to live outside the womb when their gestational age is more than 28 weeks, birthweight equal to or less than 2,5 kg (Kaminski, Goujard, & Rumeau-Rouquette, 1973), body length > 45,4-55,6 cm, head circumference > 32,7-35,8 cm (WHO, 2024). In this case, it can be concluded that the corpse can live, it weighs 2.05 kg, its chest circumference is 34 cm, its upper arm circumference is 11 cm, its body length is 47 cm, its head circumference is 32.5 cm. There are no visible organ abnormalities or birth defects that cause death in this corpse (Ningsih & Arafat, 2022).

In this case, it can be concluded that this case is a case of infanticide (Atmoko & Niufti, 2023; Langer, 1974; Tantimin et al., 2023). Some literature says that mechanical asphyxia is the easiest to perform compared to blunt force and sharp force of all infanticides (Afandi et al., 2008; Overpeck, Benner, Trumble, Trifletti, & Berendes, 1998; Väli, Lang, Soonets, Talumäe, & Grjibovski, 2007). Some other indicators that this was an infanticide case were that the body was found on the riverbank. In infanticide cases, 95% of the babies are born outside the hospital, and 71% are born in the perpetrator's home (Afandi et al., 2008; Atmoko & Niufti, 2023; Overpeck et al., 1998). According to Abraham Maslow (Ashari, Wahyuni, & Kusmiadi, 2023; Nurwatie, Fauzia, & Akbar, 2016), a person can kill due to low self-confidence, feelings of not being able to fulfil their needs, weak, helpless and worthless, so some supporting indicators of suspects can commit infanticide are people with low education, unmarried and under 19 years of age (Afandi et al., 2008; Atmoko & Niufti, 2023; Sulmustakim, 2021; Susilaningsih, 2004). Several other studies explain that the perpetrators of infanticide are women with low social, occupational, and economic status, or the perpetrators are involved in infidelity (Lonza, 2002; Sulmustakim, 2021; Susilaningsih, 2004). Other predictors include the suspect never had a

pregnancy examination (Afandi et al., 2008; Friedman, Horwitz, Ph, & Resnick, 2005) and mothers with psychiatric disorders (Dekawati & Marbun, 2022; Sulmustakim, 2021; Susilaningsih, 2004).

Conclusion

On external examination, it was found that the corpse's skin was peeling all over the body, and finding support signs of asphyxia such as the blood vessels of the eyes and blueness of the mucosa of the lips. In contrast, internal examination results are dilation of blood vessels in the brain and a severe head injury that led to bleeding all over the scalp. The infant had severe neck injuries. While supporting examination results, the lungs are mosaic, and both lungs are buoyant. There are no other tests that are used to find out that the baby was born alive, such as Wreden's test and Bresslau's test, because internal organs such as the intestines, stomach, and others have experienced advanced decay. It can be concluded that the death is unnatural because of suffocation. In comparison, the mechanism of death is due to asphyxia or airway obstruction because of severe neck injury. The estimated time of death was more than one day before the examination.

References

Afandi, D., Hertian, S., Atmadja, D. S., & Widjaja, I. R. (2008). Pembunuhan Anak Sendiri (PAS) Dengan

Kekerasan Multipel Infanticide with Multiple Injury- Case Report. *MKI*, 58(9), 355–359.

Amelinda, A., Hoediyanto, H., & Kalanjati, V. P. (2018). Profil Kasus Pembunuhan Anak di Departemen Ilmu Kedokteran Forensik dan Medikolegal RSUD Dr. Soetomo. *EJKI*, 6(1), 50–52. <https://doi.org/10.23886/ejki.6.7214.Abstrak>

Ashari, Wahyuni, N. S., & Kusmiadi, M. E. (2023). MOTIF KASUS PEMBUNUHAN BERENCANA TINJAUAN DINAMIKA PSIKOLOGI MOTIVE OF PLANNED MURDER CASE REVIEW OF PSYCHOLOGICAL DYNAMIC, 02(1), 1–25.

Atmoko, W. D., & Niufti, A. D. M. (2023). INFANTICIDE: A CASE REPORT. *Jurnal Ilmiah Kohesi*, 7(1), 1–5. Retrieved from <https://kohesi.sciencemakarioz.org/index.php/JIK/article/view/374>

Dekawati, G., & Marbun, W. (2022). Pendekatan Teori Criminal Thinking Pada Kasus Pembunuhan Anak Oleh Anak. *Krisna Law: Jurnal Mahasiswa Fakultas Hukum Universitas Krisnadwipayana*, 4(1), 59–67. Retrieved from <https://doi.org/10.37893/krisnalaw.v4i1.15>

- Friedman, S. H., Horwitz, S. M., Ph, D., & Resnick, P. J. (2005). Reviews and Overviews Child Murder by Mothers : A Critical Analysis of the Current State of Knowledge and a Research Agenda. *American Journal of Psychiatry*, 162(9), 1578–1587. Retrieved from <https://doi.org/10.1176/appi.ajp.162.9.1578>
- Kaminski, M., Goujard, J., & Rumeau-Rouquette, C. (1973). Prediction of Low Birthweight and Prematurity by a Multiple Regression Analysis with Maternal Characteristics Known since the Beginning of the Pregnancy, 2(2), 195–204.
- Khoiriah, A., & Pratiwi, T. (2019). FAKTOR-FAKTOR YANG BERPENGARUH TERHADAP KEJADIAN ASFIKSIA PADA BAYI BARU LAHIR. *Jurnal'Aisyiyah Medika*, 4. Retrieved from <https://doi.org/10.36729/jam.v4i2.218>
- Langer, W. L. (1974). INFANTICIDE : A HISTORICAL SURVEY. *The Journal of Psychohistory*, 1(3), 353.
- Lonza, N. (2002). “ TWO SOULS LOST ”: INFANTICIDE IN THE REPUBLIC OF DUBROVNIK (1667-1808). *Dubrovnik Annals*, 39(6), 67–107. Retrieved from <https://hrcak.srce.hr/18551>
- Ningsih, T., & Arafat, M. R. (2022). ILMU KEDOKTERAN FORENSIK SEBAGAI ILMU BANTU DALAM PENEGAKAN HUKUM PIDANA DI INDONESIA. *Widya Yuridika: Jurnal Hukum*, 5(1), 157–164. Retrieved from <https://doi.org/10.31328/wy.v5i1.2504>
- Nurwatie, A., Fauzia, R., & Akbar, S. N. (2016). PERSPEKTIF PSIKOLOGI HUMANISTIK ABRAHAM MASLOW DALAM MENINJAU MOTIF PELAKU PEMBUNUHAN PERSPECTIVE OF ABRAHAM MASLOW’S HUMANISTIC PSYCHOLOGY IN REVIEWING MOTIVE OF MURDER. *Jurnal Ecopsy*, 1(4). Retrieved from <http://dx.doi.org/10.20527/ecopsy.v1i4.503>
- Oberman, M. (2001). Understanding infanticide in context: Mothers who kill, 1870-1930 and today. *J. Crim. L. & Criminology*, 92, 707.
- Overpeck, M. D., Benner, R., Trumble, A., Trifletti, L., & Berendes, H. (1998). Risk factors for infant homicide in the United States. *New England Journal of Medicine*, 339(17), 1211–1216. Retrieved from [10.1056/NEJM199810223391706](https://doi.org/10.1056/NEJM199810223391706)
- Pradhika, P. (2011). *Kajian Yuridis Kesesuaian Alat Bukti Keterangan Terdakwa dengan Visum Et Repertum (Studi Kasus Pembunuhan dengan*

- Modus Asfiksia Nomor Register Perkara: PDM-43/KNYAR/Ep. 1/0309*). SURAKARTA.
- Radja, J. J., Saragih, R., & Henok, A. H. (2023). ANALISIS YURIDIS PENEGAKAN HUKUM DAN KEADILAN DALAM TINDAK PIDANA PEMBUNUHAN ANAK YANG BARU LAHIR OLEH SEORANG IBU. *Honeste Vivere*, 33(2), 185–198. Retrieved from <https://doi.org/10.55809/hv.v33i2.255>
- Shkrum, M. J. (2007). *Forensic Pathology of Trauma*. Canada: Humana Press.
- Sulmustakim, A. (2021). Kedudukan Psikologi Forensik dalam Penanganan Pelaku Tindak Pidana Pembunuhan dengan Kekerasan terhadap Anak. *Journal of Law (Jurnal Ilmu Hukum)*, 6(1), 86–98.
- Susanti, R. (2012). Kematian tahanan di ruang sel polisi kontroversi pembunuhan atau bunuh diri dilihat dari sudut pandang ilmu kedokteran forensik. *Majalah Kedokteran Andalas*, 36(1), 112–120. Retrieved from [10.22338/mka.v36.i1.p113-120.2012](https://doi.org/10.22338/mka.v36.i1.p113-120.2012)
- Susilaningsih, T. (2004). Bentuk dan upaya penanganan kekerasan pada anak. *Perspektif*, 9(1), 62–77. Retrieved from [10.30742/perspektif.v9il.264](https://doi.org/10.30742/perspektif.v9il.264)
- Tantimin, Febriyani, E., & Putra, D. (2023). Tinjauan Putusan 18 / Pid . Sus-Anak / 2020 Pn Unh Terkait Kinderdoodslag Oleh Anak Di Bawah Usia Dalam Kontekstual Tindak Pidana Pembunuhan. *Journal Of Social Science Research*, 3(4), 7010–7024. Retrieved from <https://doi.org/10.31004/innovative.v3i4.4153>
- Väli, M., Lang, K., Soonets, R., Talumäe, M., & Grjibovski, A. M. (2007). Childhood deaths from external causes in Estonia , 2001 – 2005. *BMC Public Health*, 7, 1–7. <https://doi.org/10.1186/1471-2458-7-158>
- Afandi, D., Hertian, S., Atmadja, D. S., & Widjaja, I. R. (2008). Pembunuhan Anak Sendiri (PAS) Dengan Kekerasan Multipel Infanticide with Multiple Injury- Case Report. *MKI*, 58(9), 355–359.
- Amelinda, A., Hoediyanto, H., & Kalanjati, V. P. (2018). Profil Kasus Pembunuhan Anak di Departemen Ilmu Kedokteran Forensik dan Medikolegal RSUD Dr. Soetomo. *EJKI*, 6(1), 50–52. <https://doi.org/10.23886/ejki.6.7214.Abstrak>
- Ashari, Wahyuni, N. S., & Kusmiadi, M. E. (2023). MOTIF KASUS PEMBUNUHAN BERENCANA TINJAUAN DINAMIKA PSIKOLOGI MOTIVE OF

- PLANNED MURDER CASE REVIEW OF PSYCHOLOGICAL DYNAMIC, *02*(1), 1–25.
- Atmoko, W. D., & Niufti, A. D. M. (2023). INFANTICIDE: A CASE REPORT. *Jurnal Ilmiah Kohesi*, *7*(1), 1–5. Retrieved from <https://kohesi.sciencemakarioz.org/index.php/JIK/article/view/374>
- Dekawati, G., & Marbun, W. (2022). Pendekatan Teori Criminal Thinking Pada Kasus Pembunuhan Anak Oleh Anak. *Krisna Law: Jurnal Mahasiswa Fakultas Hukum Universitas Krisnadwipayana*, *4*(1), 59–67. Retrieved from <https://doi.org/10.37893/krisnalaw.v4i1.15>
- Friedman, S. H., Horwitz, S. M., Ph, D., & Resnick, P. J. (2005). Reviews and Overviews Child Murder by Mothers : A Critical Analysis of the Current State of Knowledge and a Research Agenda. *American Journal of Psychiatry*, *162*(9), 1578–1587. Retrieved from <https://doi.org/10.1176/appi.ajp.162.9.1578>
- Kaminski, M., Goujard, J., & Rumeau-Rouquette, C. (1973). Prediction of Low Birthweight and Prematurity by a Multiple Regression Analysis with Maternal Characteristics Known since the Beginning of the Pregnancy, *2*(2), 195–204.
- Khoiriah, A., & Pratiwi, T. (2019). FAKTOR-FAKTOR YANG BERPENGARUH TERHADAP KEJADIAN ASFIKSIA PADA BAYI BARU LAHIR. *Jurnal'Aisyiyah Medika*, *4*. Retrieved from <https://doi.org/10.36729/jam.v4i2.218>
- Langer, W. L. (1974). INFANTICIDE : A HISTORICAL SURVEY. *The Journal of Psychohistory*, *1*(3), 353.
- Lonza, N. (2002). “ TWO SOULS LOST ”: INFANTICIDE IN THE REPUBLIC OF DUBROVNIK (1667-1808). *Dubrovnik Annals*, *39*(6), 67–107. Retrieved from <https://hrcak.srce.hr/18551>
- Ningsih, T., & Arafat, M. R. (2022). ILMU KEDOKTERAN FORENSIK SEBAGAI ILMU BANTU DALAM PENEGAKAN HUKUM PIDANA DI INDONESIA. *Widya Yuridika: Jurnal Hukum*, *5*(1), 157–164. Retrieved from <https://doi.org/10.31328/wy.v5i1.2504>
- Nurwatie, A., Fauzia, R., & Akbar, S. N. (2016). PERSPEKTIF PSIKOLOGI HUMANISTIK ABRAHAM MASLOW DALAM MENINJAU MOTIF PELAKU PEMBUNUHAN PERSPECTIVE OF ABRAHAM MASLOW'S HUMANISTIC PSYCHOLOGY IN REVIEWING

- MOTIVE OF MURDER. *Jurnal Ecopsy*, 1(4). Retrieved from <http://dx.doi.org/10.20527/ecopsy.v1i4.503>
- Oberman, M. (2001). Understanding infanticide in context: Mothers who kill, 1870-1930 and today. *J. Crim. L. & Criminology*, 92, 707.
- Overpeck, M. D., Benner, R., Trumble, A., Trifletti, L., & Berendes, H. (1998). Risk factors for infant homicide in the United States. *New England Journal of Medicine*, 339(17), 1211–1216. Retrieved from [10.1056/NEJM199810223391706](https://doi.org/10.1056/NEJM199810223391706)
- Pradhika, P. (2011). *Kajian Yuridis Kesesuaian Alat Bukti Keterangan Terdakwa dengan Visum Et Repertum (Studi Kasus Pembunuhan dengan Modus Asfiksia Nomor Register Perkara: PDM-43/KNYAR/Ep. 1/0309)*. SURAKARTA.
- Radja, J. J., Saragih, R., & Henok, A. H. (2023). ANALISIS YURIDIS PENEGAKAN HUKUM DAN KEADILAN DALAM TINDAK PIDANA PEMBUNUHAN ANAK YANG BARU LAHIR OLEH SEORANG IBU. *Honeste Vivere*, 33(2), 185–198. Retrieved from <https://doi.org/10.55809/hv.v33i2.255>
- Shkrum, M. J. (2007). *Forensic Pathology of Trauma*. Canada: Humana Press.
- Sulmustakim, A. (2021). Kedudukan Psikologi Forensik dalam Penanganan Pelaku Tindak Pidana Pembunuhan dengan Kekerasan terhadap Anak. *Journal of Law (Jurnal Ilmu Hukum)*, 6(1), 86–98.
- Susanti, R. (2012). Kematian tahanan di ruang sel polisi kontroversi pembunuhan atau bunuh diri dilihat dari sudut pandang ilmu kedokteran forensik. *Majalah Kedokteran Andalas*, 36(1), 112–120. Retrieved from [10.22338/mka.v36.i1.p113-120.2012](https://doi.org/10.22338/mka.v36.i1.p113-120.2012)
- Susilaningsih, T. (2004). Bentuk dan upaya penanganan kekerasan pada anak. *Perspektif*, 9(1), 62–77. Retrieved from [10.30742/perspektif.v9il.264](https://doi.org/10.30742/perspektif.v9il.264)
- Tantimin, Febriyani, E., & Putra, D. (2023). Tinjauan Putusan 18 / Pid . Sus-Anak / 2020 Pn Unh Terkait Kinderdoodslag Oleh Anak Di Bawah Usia Dalam Kontekstual Tindak Pidana Pembunuhan. *Journal Of Social Science Research*, 3(4), 7010–7024. Retrieved from <https://doi.org/10.31004/innovative.v3i4.4153>
- Väli, M., Lang, K., Soonets, R., Talumäe, M., & Grjibovski, A. M. (2007). Childhood deaths from external causes in Estonia , 2001 – 2005. *BMC Public Health*, 7, 1–7. <https://doi.org/10.1186/1471-2458-7-158>