



Vasospastic Angina and its Contemporary Review of Pathophysiology, Diagnosis and Management

Sidhi Laksono Purwowiyoto^{1,2*}, Lidya Pertiwi Suhandako³

¹ Department of Cardiology and Vascular Medicine, Siloam Diagram Heart Hospital, Depok, Indonesia

² Faculty of Medicine, Universitas Muhammadiyah Prof Dr Hamka, Tangerang, Indonesia

³ Faculty of Medicine, Universitas Airlangga, Surabaya, Indonesia

*Corresponding Author: sidhilaksono@uhamka.ac.id

DOI: 10.33086/iimj.v5i2.5760

ARTICLE INFO

Keywords:
coronary artery
spasm, endothelial
dysfunction,
vascular smooth
muscle
hyperreactivity,
vasospastic angina

Submitted: March
21th 2024
Reviewed: April
15th 2024
Accepted: May 6th
2024

ABSTRACT

Introduction: Patients presenting with angina who have an unobstructed coronary artery is almost 50% incidence. Patients with chest pain in the absence of obstructive coronary artery disease (CAD) remain a challenge. These patients undergoing invasive coronary angiography do not have epicardial coronary disease obstructive enough to explain these symptoms. This needs to be considered as it can lead to very serious arrhythmias leading to a fatal heart attack. The exact pathophysiological mechanisms behind this phenomenon remain partially unclear, leading to restricted treatment options for affected patients. This review offers an in-depth overview of the pathophysiological mechanisms of vasospastic angina and explores the treatment choice. Additionally, this review evaluate the existing diagnostic methods for patients presumed of having vasospastic angina.

Result:

Coronary microvascular tone and subsequently, its blood flow is regulated through various vasodilating and vasoconstricting mechanisms. Coronary endothelial dysfunction and vascular smooth muscle hyperreactivity are proposed mechanism causing coronary artery spasms. This may cause transient ST-Elevations, malignant arrhythmias and significant heart blocks. Various non-invasive and invasive exams may identify and differentiate these variant anginas.

Conclusions:

Vasospastic angina can be precisely diagnosed in a catheter laboratory, with pharmacological treatment being the primary management approach.

Introduction

Vasospastic angina (VSA) involves sudden coronary flow reduction due to spasms in either the epicardial or microvascular vessels, resulting in myocardial ischemia and angina (Prinzmetal et al., 1959a). A large proportion of patients perform provocative tests and undergo invasive coronary

angiography, but have no epicardial coronary disease to explain their symptoms (Jespersen et al., 2012; Knuuti et al., 2020a). This condition is categorized as angina with non-obstructive coronary arteries (ANOCA) and ischemia with non-obstructive coronary arteries (INOCA) when there is evidence of myocardial ischemia (Kunadian et al., 2020). INOCA

encompasses the endotypes of epicardial coronary vasospasm and coronary microvascular dysfunction (CMD) (Beltrame et al., 2015a; Ong et al., 2018). microvascular angina is the result of myocardial ischaemia caused by CMD. CMD has been researched for a long time and is well known for its worse prognosis. (Sara et al., 2015; Shimokawa et al., 2021). Additionally, CMD significantly affects quality of life due to the difficulty in

managing symptoms, leading to higher rates of emergency room visits, hospital admissions, and invasive procedures (Jespersen et al., 2013). This literature review aims to ensure comprehensive insights into the latest updates of VSA, covering its pathophysiology, diagnostic methods, and latest treatments. A brief overview of vasospastic angina and its management is presented in Figure 1.

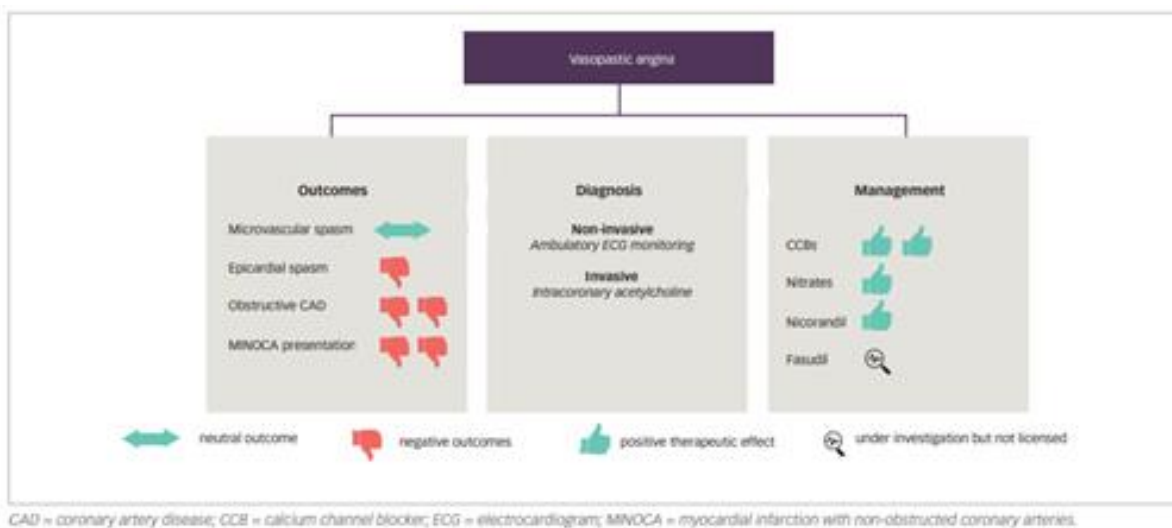


Figure 1. Summary of vasospastic angina and its management

Vasospastic angina refers to a type of angina caused by a spasm in the coronary artery, characterized by sudden, severe vasoconstriction of an epicardial artery segment, leading to a significant decrease in blood flow (J. C. Kaski et al., 1989). This condition was described as a unique pathology causing chest tightness at rest, notable ST-segment elevation, also higher incidence of ventricular arrhythmias

compared to classic effort angina. (Prinzmetal et al., 1959b).

In its classic form, vasospastic angina (Prinzmetal's variant angina) typically occurs at rest, but in some patients, it can also be triggered by physical exertion or stress. The spasm can happen at the site both significant and non-significant coronary stenosis. Moreover, spasm can also occur in the epicardial arteries which are normal in

the angiographical analysis and may sometimes affect multiple coronary segments (multifocal spasm).

This condition most commonly appears in adults aged 50 to 60 years and has a male-to-female prevalence ratio of 5:1. Notably, more than half of women with stable chest pain who undergo coronary angiography (CAG) have no obstructive coronary artery disease (CAD), compared to only one-third of men. (Jespersen et al., 2012; Prinzmetal et al., 1959a).

Vasospastic angina has been recognized for many years, yet it remains under-diagnosed and insufficiently investigated. Vasospastic angina, despite this, has the dangerous potential to cause severe arrhythmias leading to VF and death. The incidences of this condition are prevalent in Asia, possibly because provocative tests are performed oftentimes. In contrast, such tests are less frequently performed in France, possibly because they often yield negative results.

Pathophysiology

Prinzmetal and colleagues suggested that variant angina pectoris results from the temporary occlusion of a large, diseased coronary artery with a narrow lumen due to increased vessel wall tone (Prinzmetal et al., 1959a). Later studies confirmed that coronary artery spasm causes myocardial ischemia in patients with variant angina,

occurs in apparently functional coronary arteries and at areas of organic stenosis (Curry et al., 1979; Higgins et al., 1976). Yasue et al. found that in 70% of Japanese patients with coronary artery spasm, coronary arteriograms appear normal or nearly normal (Yasue & Kugiyama, 1997). Figure 4 presents representative coronary arteriograms showing coronary artery spasm in a patient with variant angina (JCS, 2014; Kishida et al., 1985; Yasue et al., 2008). Diagnostic provocation methods using acetylcholine and ergonovine have been developed to identify coronary artery spasm. However, this test should only be performed by a doctor who has the competence and is carried out in health services that have adequate infrastructure in the angiography laboratory. This is due to the fact that this procedure can cause serious complications (Yasue et al., 2008). Although the exact cause of coronary artery spasm is still unclear, endothelial dysfunction and increased vascular smooth muscle contractility have been suggested to be the two main mechanisms. (Shimokawa, 2000; Yasue et al., 2008).

The coronary vasculature is composed of epicardial arteries (>400 μm), prearteriolar vessels (400–100 μm), arterioles (<100 μm), and capillaries (<10 μm) (J.-C. Kaski et al., 2018). The balance between epicardial coronary vessels and the microcirculation is essential for proper

myocardial perfusion. The prearteriolar vessels are responsible for sustaining pressure at the downstream arteriolar source in a limited range. This occurs regardless of fluctuations in the pressure or flow of coronary perfusion. Distal segments are responsive to pressure changes, whereas proximal segments are responsive to flow changes. These vasomotor actions are primarily driven by myogenic mechanisms rather than the direct action of myocardial metabolites (Sinha et al., 2020). The microvascular compartment, including

arterioles and capillaries, regulates coronary blood flow (CBF) over a wide range of perfusion pressures by adjusting vessel diameter through myogenic and metabolic mechanisms (Recio-Mayoral et al., 2013). In this process, nitric oxide (NO) and other vasodilator substances produced by the endothelium play a critical role in modulating vascular tone and, consequently, myocardial blood flow (Tonet et al., 2021). Figure 2 illustrates the macro/microcirculation angina endotypes.

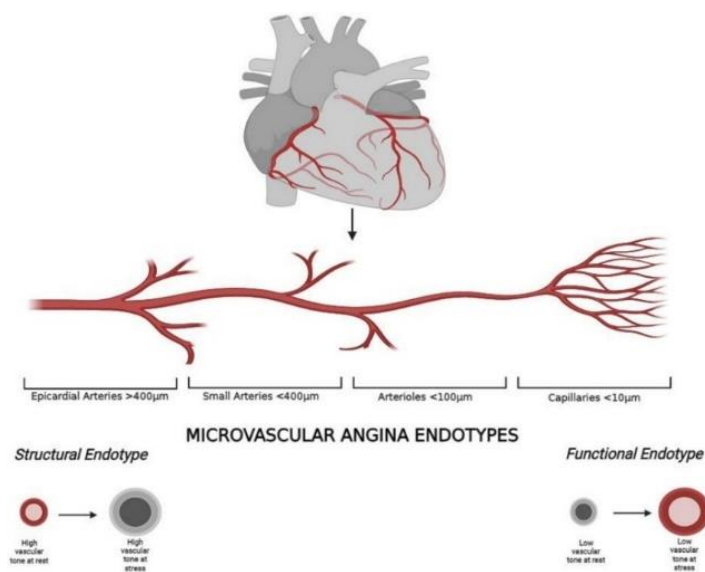


Figure 2. Coronary macro- and microcirculation and microvascular angina

Coronary Endothelial Dysfunction

Endothelial-dependent dysfunction results from the pathological constriction of a vessel or vascular bed. Diffuse distal epicardial and microvascular constriction leads to ST depression and can manifest as either rest or stress angina (Ong et al.,

2012). Diffuse epicardial constriction is likely due to the same processes as microvascular endothelial dysfunction and carries similar risks (Halcox et al., 2002). Without coronary vasomotion studies, clinically distinguishing between epicardial endothelial dysfunction and microvascular

angina is difficult. Diffuse epicardial constriction suggesting that microvascular constriction may initiate the process and propagate proximally (Ong et al., 2013). Endothelial dysfunction significantly contributes to chest pain without obstructive coronary disease, which will be discussed further in this review.

The vascular endothelium regulates local vascular tone by inducing smooth muscle relaxation and vasodilation through the release of nitric oxide (NO), prostacyclin (PGI₂), and endothelium-derived hyperpolarizing factor (EDHF), or by causing vasoconstriction through the release of thromboxane A₂, endothelin-1, or free radicals.(Epstein et al., 1990). Imbalances favoring microvascular constriction among these factors may lead to endovascular dysfunction. NO is the most studied of these factors, as it is the primary mediator of vascular tone in conduit vessels.

Under normal conditions, shear stress activates mechanoreceptors on endothelial cells, prompting endothelial NO synthase (eNOS) to convert L-arginine into NO with the aid of its cofactor tetrahydrobiopterin (Förstermann & Münzel, 2006). However, conditions like systemic inflammation can hinder eNOS's ability to produce NO, a phenomenon referred to as 'eNOS uncoupling' (Förstermann & Münzel, 2006). Previous studies have shown

decreased nitric oxide action in with coronary artery spasm conditions (Kugiyama et al., 1996).

Additionally, research suggests that coronary endothelial dysfunction contributes to the development of coronary artery disease. Animal models with eNOS gene mutations are particularly prone to coronary artery spasm (Nakayama et al., 1999). Acetylcholine (ACh) is often used in catheter labs to evaluate coronary endothelial integrity due to its dual action on muscarinic receptors in both endothelial and vascular smooth muscle cells.

Dysfunctional endothelial cells release endothelin-1 (ET-1), a powerful vasoconstrictor. There was an elevated levels of ET-1 in the coronary sinus plasma of patients who exhibit coronary artery spasm during provocation tests (Toyo-oka et al., 1991). Rho kinase, activated downstream of endothelin-1, significantly contributes to vascular smooth muscle constriction and is implicated in the vasospastic response in patients with endothelial dysfunction and microvascular angina (Mohri et al., 2003).

Ford et al. (2018) demonstrated reduced vasorelaxation in response to ACh and increased vasoconstriction to ET-1 in gluteal biopsy samples, suggesting systemic endothelial dysfunction in these patients. Additionally, Reriani et al. (2010) reported improved coronary endothelial function in

patients with non-obstructive coronary artery disease in response to treatment with an endothelin A receptor antagonist. Yet, although coronary endothelial dysfunction is involved in coronary artery spasm, we should note that an underlying endothelial dysfunction is not present in all vessels predisposed to spasm. (Yamamoto et al., 1992).

This indicates that there could be another factor contributing to coronary artery spasm, even when coronary endothelial dysfunction is not present. The potential role of vascular smooth muscle hyperreactivity as this additional mechanism will be further explored in the following sections.

Vascular Smooth Muscle Hyperreactivity

Porcine models of coronary spasm have shown that the calcium handling mechanism of contractile proteins and the expression of vasoconstrictor-promoting cellular receptors remain unchanged (Miyata et al., 2000; Satoh et al., 1990). Additionally, animal studies have implicated the protein kinase C-mediated pathway in the development of coronary artery spasm (Kadokami et al., 1996). These findings suggest that the initial trigger of coronary artery spasm is calcium (Ca^{2+}) influx through L-type Ca^{2+} channels in vascular smooth muscle (VSM) cells, potentially enhanced through a protein

kinase C-dependent mechanism. Indeed, functional upregulation of L-type Ca^{2+} channels at spastic sites has been demonstrated in porcine models of coronary spasm (Kuga et al., 2000).

Animal research has also shown upregulation of rho kinase at spastic sites, which plays a critical role in inducing VSM hypercontraction by inhibiting myosin light chain phosphatase (Kandabashi et al., 2000). The rho kinase inhibitor fasudil has been found to significantly reduce acetylcholine - induced coronary vasoconstriction in patients with coronary artery spasm (Masumoto et al., 2002). It has been proposed that while coronary endothelial dysfunction may predominantly contribute to diffuse multi-vessel spasm, vascular smooth muscle hyperreactivity likely plays a greater role in focal spasm.

There are interaction of two components that result in coronary spasm. First, the local hyperreactivity to vasoconstrictor stimuli in coronary segments. Second, ongoing vasoconstrictor stimuli triggering spasm in hyperreactive segments (J.C. Kaski et al., 1986). This hyperreactivity in vascular smooth muscle is likely due to abnormal regulation of myofibril contraction post-receptorally, as indicated by the ability to induce spasm with several stimuli acting on different cellular receptors and limited effectiveness of specific receptor antagonists (i.e alpha-blockers, serotonin

antagonists) in preventing angina attacks in these patients (Lanza, 2003; Lanza et al., 1996).

Several studies have suggested that increased membrane Na⁺-H⁺ activity, a key regulator of intracellular pH, leads to abnormal vasoreactivity. (Myerburg et al., 1992). In a further study, rho kinase activity and impaired K⁺-ATP-dependent channel function may be among the cellular pathways involved in coronary spasm (Masumoto et al., 2002).

Clinical Findings and Outcome

Prinzmetal et al. noted that patients experiencing chest pain without obstructive coronary artery disease (CAD) present a clinical challenge. They observed distinct differences in the clinical manifestation of variant angina compared to classic effort angina. Variant angina typically manifests as pain occurring at rest or during normal activities, rather than being triggered by exercise. Electrocardiograms during these episodes show ST segment elevations with reciprocal depressions (Prinzmetal et al., 1959a).

Ambulatory electrocardiographic monitoring has revealed a circadian pattern

in ischemic episodes among patients with variant angina, with transient ST-segment elevations often occurring from midnight to early morning, peaking around 5 o'clock in the morning (Kishida et al., 1985; Yasue & Kugiyama, 1997).

While Prinzmetal et al. reported that variant angina pain occurs primarily at rest or during ordinary activities (Prinzmetal et al., 1959a), Yasue et al. found that anginal attacks can also occur during mild exercise in the morning, but it is possible that they can occur in the evening during intense exercise, although this is rare. (Yasue et al., 2008; Yasue & Kugiyama, 1997). This circadian variation in exercise capacity is common among most patients with variant angina (Yasue et al., 2008; Yasue & Kugiyama, 1997).

Based on previous studies, in variant angina showed that 82% of ischaemic episodes were asymptomatic thus becoming an important point. As well as syncopal episodes, syncope occurred in 12.5% of patients with variant angina. (KISHIDA et al., 1996)

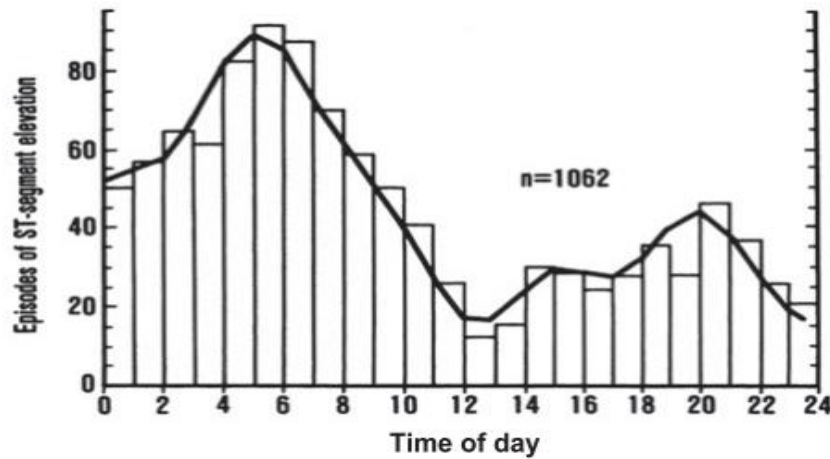


Figure 4. Circadian in ST segment elevation episodes in patients with variant angina

Source: Kusama et al., (2011)

Transient ST-segment elevations accompanied by reciprocal depressions, indicating transmural myocardial ischemia, are typical electrocardiographic findings in variant angina. These ST-segment elevations typically correspond to the distribution of the affected major coronary artery. During attacks, additional electrocardiographic changes may include a taller and broader R wave, disappearance of the S wave, and an elevated T wave (Prinzmetal et al., 1959a). Negative U waves may also appear intermittently during attacks, often in the same leads displaying ST-segment elevation. These U

waves typically emerge as the ST-segment elevation begins to subside, gradually becoming more prominent before eventually disappearing (Kishida et al., 1985).

Severe arrhythmias, such as ventricular tachycardia (Figure 5), high-degree atrioventricular block (Figure 6), and bradyarrhythmia leading to syncope, can occasionally occur during a variant angina attack (Kishida et al., 1996). Therefore, to detect dynamic electrocardiographic changes in patients with variant angina, continuous outpatient electrocardiographic monitoring has been shown to be beneficial.

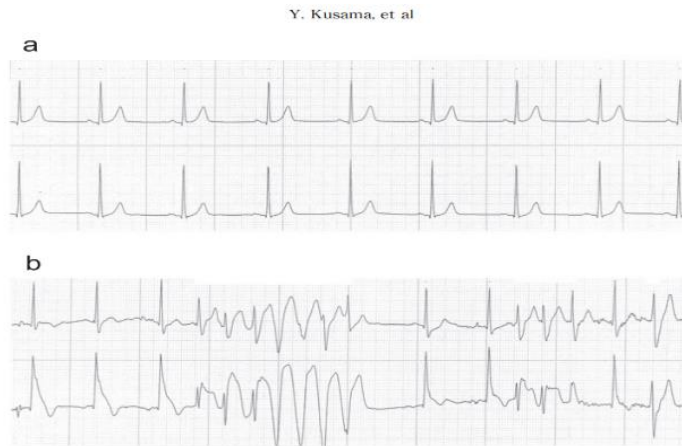


Figure 5. Ambulatory electrocardiographic recordings in a patient with variant angina. a: control recordings. b: recordings during an attack showing ST segment elevation and ventricular tachycardia.

Source: Kusama et al (2011)

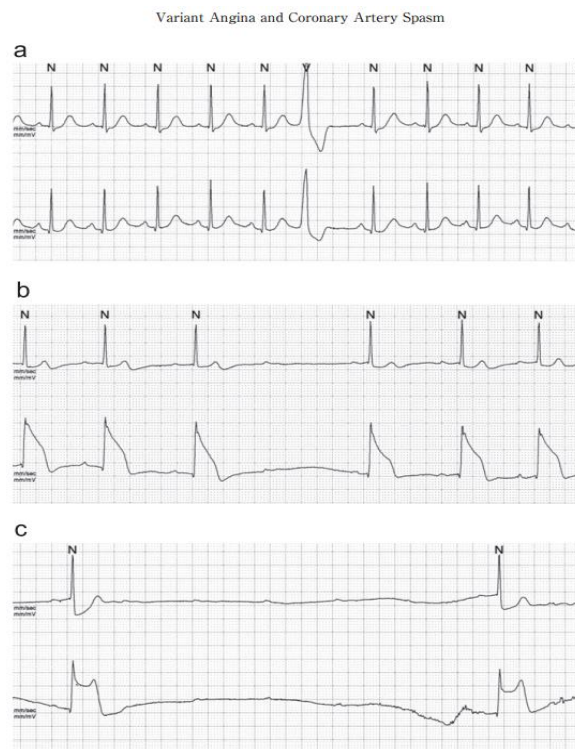


Figure 6. a: control recordings b and c: recordings during an attack in a patient with variant angina, showing ST-segment elevation and second-degree atrioventricular (AV) block (panel b) and advanced AV block (panel c).

Source: Kusama et al (2011)

Yasue et al. proposed that vasospastic angina can be diagnosed even without coronary angiography if nitroglycerin quickly relieves anginal attacks and if any

of the following criteria are met: 1) attacks occur at rest, especially during the night and early morning hours; 2) significant diurnal variation in exercise tolerance is observed,

particularly with reduced exercise capacity in the early morning; 3) attacks are accompanied by ST-segment elevation on electrocardiogram; 4) attacks are triggered by hyperventilation; or 5) attacks are alleviated by calcium channel blockers but not by beta-blockers (Yasue et al., 2008). Recently, the diagnostic criteria and diagnostic flowchart in the guidelines for the diagnosis and treatment of patients with vasospastic angina have been updated (JCS 2008; Knuuti et al., 2020b).

Diagnosis

In 2015, the Coronary Vasomotion Disorders International Study (COVADIS) group introduced standardized diagnostic criteria for vasospastic angina (VSA) to promote consistency in clinical and research practices. These criteria allow for a diagnosis of 'definitive VSA' through either coronary angiography with pharmacological stimulation or ambulatory electrocardiogram (ECG) monitoring. Both approaches are endorsed by the European Society of Cardiology and the Japanese Circulation Society for evaluating patients suspected of having VSA (Beltrame et al., 2015b).

According to COVADIS, vasospastic angina is characterized by near-total ($\geq 90\%$) occlusion of an epicardial coronary artery, leading to nitrate-responsive angina and ischemic changes on

electrocardiogram. This occlusion can occur spontaneously or in response to a provocative stimulus (Beltrame et al., 2015b). The COVADIS group delineated specific diagnostic criteria for vasospastic angina, as depicted in Figure 7 of their guidelines.

Non-invasive Assessment of Coronary Vasospasm

According to the COVADIS criteria, if an episode of spontaneous rest angina is accompanied by transient ischemic changes on the ECG and no other cause for these changes is identified, coronary artery spasm is presumed to be the underlying cause. In such cases, a definitive diagnosis of vasospastic angina may be made even bypassing formal documentation of coronary artery spasm. Yet, the documentation of ischaemic ECG alterations during spontaneous episodes of rest angina is often impractical. Additionally, coronary artery spasm frequently coexists with epicardial coronary artery disease (CAD) and/or endothelium-independent coronary dysfunction. Therefore, comprehensive assessment of coronary vascular function, such as through coronary angiography with invasive physiology evaluation (including fractional flow reserve, coronary flow reserve [CFR], acetylcholine [ACh] flow reserve [AChFR], and spasm assessment), is now considered

the preferred diagnostic approach for this patient group (Perera et al., 2023a).

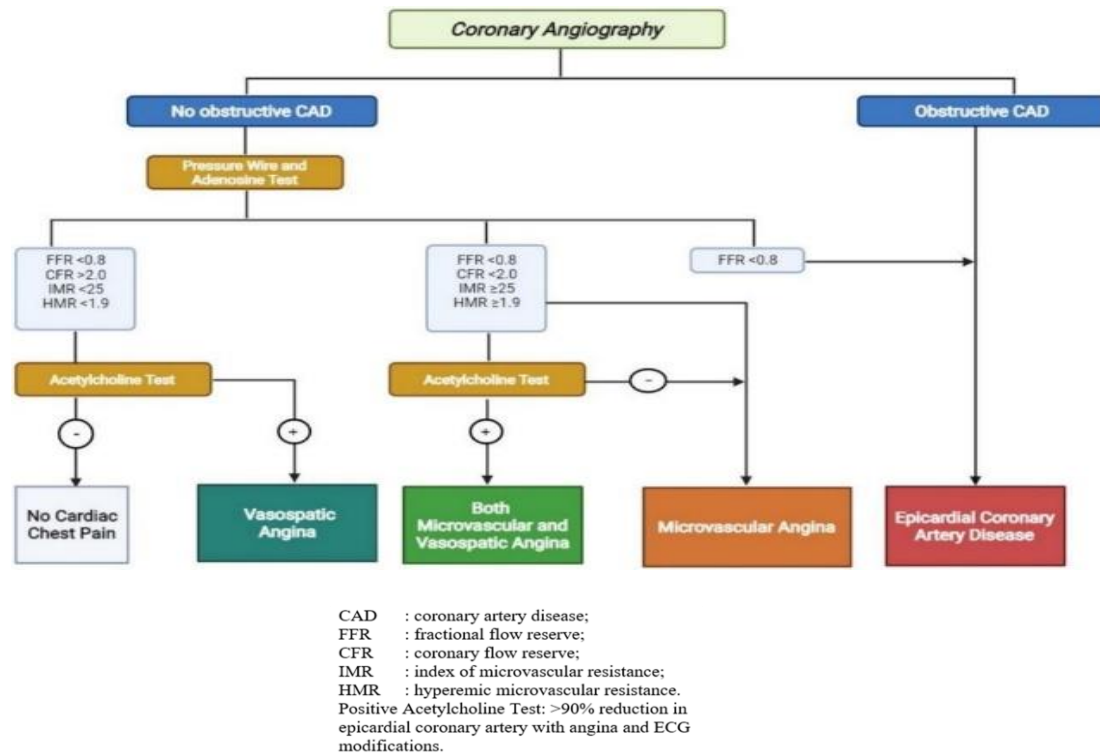


Figure 7. Diagnostic algorithm for no obstructive and obstructive coronary artery disease.

Invasive Coronary Physiology Assessment in the Catheter Laboratory

Assessment of coronary vasomotion using ACh stimulation is both feasible and safe for patients suspected of having VSA (Ong et al., 2014). It is advised that patients with angina and non-obstructive coronary artery disease (ANOCA) undergo coronary physiology assessment to identify any underlying coronary vascular dysfunction that could lead to myocardial ischemia. The Coronary Flow Reserve is the main standard used to differentiate between normal and abnormal coronary vascular function. CFR measures the ability of the coronary vessels to increase blood flow in

response to increased demand. A reduced CFR (<2,0) indicates impaired coronary vascular function and suggests potential myocardial ischemia. Epicardial artery spasm is diagnosed when an ACh bolus causes $\geq 90\%$ coronary vasoconstriction, along with ischemic ECG changes and chest pain. This diagnostic approach has shown high sensitivity and specificity for detecting coronary spasm in patients with VSA symptoms. (Beltrame et al., 2015b; Okumura et al., 1988). Microvascular spasm, on the other hand, is diagnosed when an ACh bolus induces ischemic ECG changes and chest pain without $\geq 90\%$ coronary vasoconstriction. An AChFR <1.0

with ACh bolus, indicating flow attenuation in the absence of significant epicardial spasm, also suggests microvascular spasm (Beltrame et al., 2015b). An illustrative

example of significant epicardial spasm in response to an ACh bolus is depicted in Figure 8.

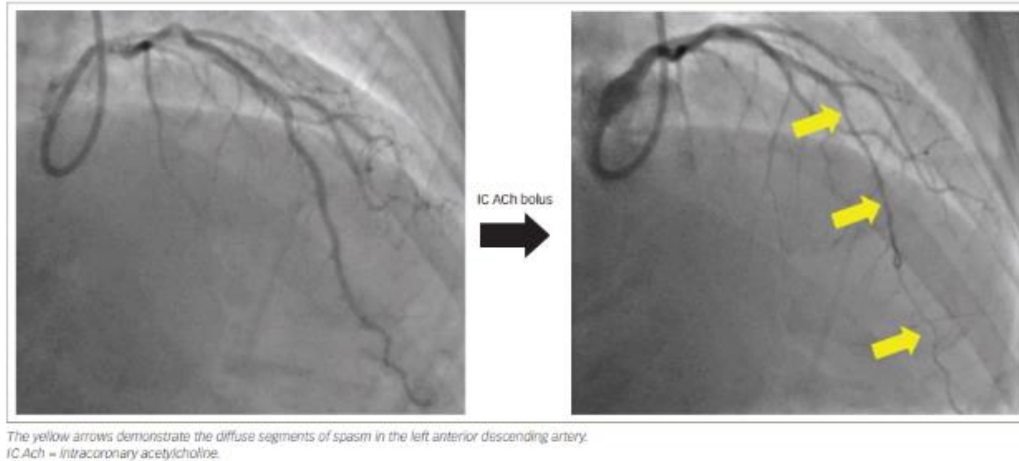


Figure 8. Coronary angiography images of the left coronary artery at baseline (left) and following an acetylcholine bolus (right) in a patient experiencing epicardial coronary artery vasospasm

The precise dose and infusion rate of ACh that matches physiological levels of coronary spasm remains unclear, as ACh can induce spasm in anyone above a certain threshold (Konst et al., 2021). This effect was demonstrated in a study examining various ACh concentrations in patients with normal epicardial arteries (Newman et al., 1990). Researchers observed an increase in epicardial vessel diameter and coronary blood flow with ACh concentrations up to 10^{-4} mol/L; however, concentrations of 10^{-3} mol/L caused significant vasoconstriction and chest pain (Newman et al., 1990). This variability led the authors to propose that the local ACh concentration

and the specific coronary vascular segment studied may greatly affect the response to ACh (Newman et al., 1990).

Furthermore, there is variability among centers regarding the diagnostic threshold for defining the degree of epicardial vasoconstriction in response to ACh. While most centers use a 90% vasoconstriction threshold, some employ different arbitrary thresholds, such as 75% vasoconstriction (Ong et al., 2014; Perera et al., 2023b). These differing thresholds can affect the sensitivity and specificity of the diagnostic process.

Indications

Provocative spasm testing carries considerable risk, so experienced personnel are required. In addition, the risks and benefits to patients must be carefully evaluated. Recommended indications for

provocative spasm testing are shown in Table 1. Based on the relative risks and benefits of the investigation these indications are classified into conventional Class I-III groups,.

Table 1. Indications for Provocative Coronary Artery Spasm Testing

Class I (strong indications)
<ul style="list-style-type: none"> • History suspicious of VSA without documented episode, especially if: <ul style="list-style-type: none"> • Nitrate-responsive rest angina, and/or • Marked diurnal variation in symptom onset/exercise tolerance, and/or • Rest angina without obstructive coronary artery disease • Unresponsive to empiric therapy • Acute coronary syndrome presentation in the absence of a culprit lesion • Unexplained resuscitated cardiac arrest • Unexplained syncope with antecedent chest pain • Recurrent rest angina following angiographically successful PCI
Class IIa (good indications)
<ul style="list-style-type: none"> • Invasive testing for non-invasive diagnosed patients unresponsive to drug therapy • Documented spontaneous episode of VSA to determine the 'site and mode' of spasm
Class IIb (controversial indications).
<ul style="list-style-type: none"> • Invasive testing for non-invasive diagnosed patients responsive to drug therapy
Class III (contra-indications)
<ul style="list-style-type: none"> • Emergent acute coronary syndrome • Severe fixed multi-vessel coronary artery disease including left main stenosis • Severe myocardial dysfunction (Class IIb if symptoms suggestive of vasospasm)
Patients without any symptoms suggestive of VSA

Management

Management of vasospastic angina (VSA) primarily involves pharmacological interventions, lifestyle modifications such as smoking cessation, and avoiding triggers

known to provoke coronary spasm, such as beta blockers and triptans. Various anti-ischemic medications are commonly prescribed for these patients.

In most cases, attacks of variant angina can be effectively controlled with antianginal drugs. However, some patients do not achieve adequate control of coronary artery spasm even with combination therapy (Yasue et al., 2008). A Japanese study defined incurable vasospastic angina as persistent angina. Even post-treatment with two different coronary vasodilators. The study found that out of 2,251 patients with angina pectoris, 921 (40.9%) had vasospastic angina, and 126 (13.7%) of

these experienced intractable symptoms. Patients with incurable vasospastic angina were generally younger at diagnosis, greater risk of smoke-related behaviour, and often had normal blood pressure compared to those with treatable vasospastic angina. (JCS Joint Working Group, 2014). Figure 9 illustrates invasive diagnostic methods and management strategies for angina in patients with non-obstructed coronary arteries.

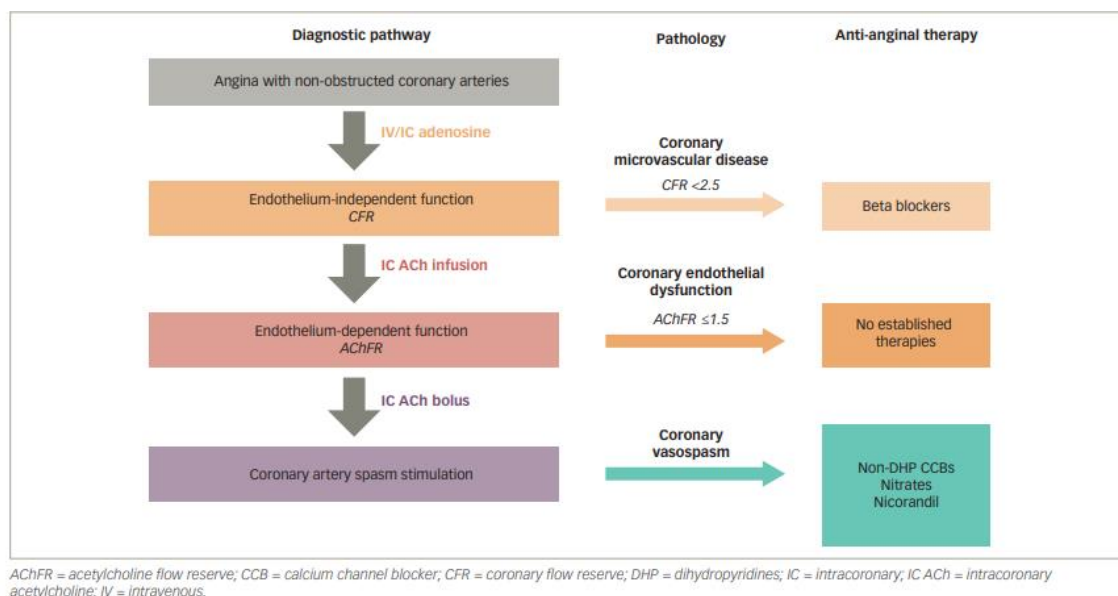


Figure 9. Examples of contemporary invasive diagnostic pathways, and management strategies, in patients with angina with non-obstructed coronary arteries

Calcium Channel Blocker CCB

Multiple therapeutic methods are used to manage vasospastic angina (VSA). Calcium channel blockers (CCBs) prevent the activation of voltage-dependent L-type Ca²⁺ channels, which reduces the activation of calcium-induced myosin light

chain kinase and suppresses inducible coronary spasm. This leads to fewer angina episodes and a better prognosis. (Goldberg et al., 1979; Ong et al., 2014).

Long-acting Nitrates

Nitrates function as nitric oxide (NO) donors, causing vasodilation, and combining CCBs with nitrates targets separate pathways involved in coronary spasm (Nishigaki et al., 2010)

Nicorandil

Nicorandil stimulates soluble guanylate cyclase, increasing cyclic guanosine monophosphate levels, and opens adenosine triphosphate-sensitive potassium channels, resulting in hyperpolarization and subsequent closure of calcium channels, thereby reducing anginal burden in VSA patients (Ginsburg et al., 1982). The Japanese Cardiology Society recommends nicorandil as Class IIa for VSA treatment, although it is second-line in European guidelines (JCS Joint Working Group, 2014).

Rho Kinase Inhibitors

Fasudil, a rho kinase inhibitor, has proven effective in reducing ACh-induced coronary artery spasm by inhibiting myosin-binding substrate and inducing vasodilation (Masumoto et al., 2002; Mohri et al., 2003). These treatments focus on essential cellular pathways in regulating coronary vasomotor function: CCBs target L-type calcium channels, nitrates release NO, nicorandil boosts cyclic guanosine monophosphate production, and endothelin receptor antagonists and rho kinase

inhibitors reduce endothelin and rho kinase-dependent vasoconstrictive mechanisms.

Pleitropic Agents

Clinical studies, including a randomized trial comparing fluvastatin and CCB combination therapy versus CCB alone, have demonstrated superior outcomes in preventing ACh-induced spasm with combination therapy (Konst et al., 2021). Registry-based studies also indicate lower rates of recurrent angina, major adverse cardiac events, and mortality at five years in VSA patients using angiotensin-converting enzyme inhibitors (Beltrame et al., 2015b). A survey on drug treatment in Japan highlighted high efficacy rates of calcium channel blockers like nifedipine, diltiazem, verapamil, and their combinations in managing variant angina, with newer agents such as benidipine and amlodipine also proving highly effective (Konst et al., 2021; Lablanche et al., 1993).

Conclusion

Vasospastic angina (VSA) can be precisely diagnosed in the catheter laboratory, ensuring accuracy and safety. Management primarily relies on pharmacotherapy, with calcium channel blockers (CCBs) and long-acting nitrates recommended as initial treatments, while nicorandil serves as a secondary option. Emerging therapies targeting specific mechanistic pathways

have demonstrated encouraging results in clinical trials. Further dialogue and investigation could aid clinicians in enhancing both diagnosis and treatment strategies for vasospastic angina.

References

- Beltrame, J. F., Crea, F., Kaski, J. C., Ogawa, H., Ong, P., Sechtem, U., Shimokawa, H., & Bairey Merz, C. N. (2015a). International standardization of diagnostic criteria for vasospastic angina. *European Heart Journal*, ehv351. <https://doi.org/10.1093/eurheartj/ehv351>
- Beltrame, J. F., Crea, F., Kaski, J. C., Ogawa, H., Ong, P., Sechtem, U., Shimokawa, H., & Bairey Merz, C. N. (2015b). International standardization of diagnostic criteria for vasospastic angina. *European Heart Journal*, ehv351. <https://doi.org/10.1093/eurheartj/ehv351>
- Curry, R. C., Pepine, C. J., Sabom, M. B., & Conti, C. R. (1979). Similarities of ergonovine-induced and spontaneous attacks of variant angina. *Circulation*, 59(2), 307–312. <https://doi.org/10.1161/01.CIR.59.2.307>
- Epstein, F. H., Vane, J. R., Änggård, E. E., & Botting, R. M. (1990). Regulatory Functions of the Vascular Endothelium. *New England Journal of Medicine*, 323(1), 27–36. <https://doi.org/10.1056/NEJM199007053230106>
- Ford, T. J., Rocchiccioli, P., Good, R., McEntegart, M., Eteiba, H., Watkins, S., Shaukat, A., Lindsay, M., Robertson, K., Hood, S., Yii, E., Sidik, N., Harvey, A., Montezano, A. C., Beattie, E., Haddow, L., Oldroyd, K. G., Touyz, R. M., & Berry, C. (2018). Systemic microvascular dysfunction in microvascular and vasospastic angina. *European Heart Journal*, 39(46), 4086–4097. <https://doi.org/10.1093/eurheartj/ehy529>
- Förstermann, U., & Münzel, T. (2006). Endothelial Nitric Oxide Synthase in Vascular Disease. *Circulation*, 113(13), 1708–1714. <https://doi.org/10.1161/CIRCULATIONAHA.105.602532>
- Ginsburg, R., Lamb, I. H., Schroeder, J. S., Hu, M., & Harrison, D. C. (1982). Randomized double-blind comparison of nifedipine and isosorbide dinitrate therapy in variant angina pectoris due to coronary artery spasm. *American Heart Journal*, 103(1), 44–48. [https://doi.org/10.1016/0002-8703\(82\)90527-0](https://doi.org/10.1016/0002-8703(82)90527-0)
- Goldberg, S., Reichek, N., Wilson, J., Hirshfeld, J. W., Muller, J., & Kastor, J.

- A. (1979). Nifedipine in the treatment of Prinzmetal's (variant) angina. *The American Journal of Cardiology*, 44(5), 804–810. [https://doi.org/10.1016/0002-9149\(79\)90201-7](https://doi.org/10.1016/0002-9149(79)90201-7)
- Guidelines for Diagnosis and Treatment of Patients With Vasospastic Angina (Coronary Spastic Angina) (JCS 2013). (2014). *Circulation Journal*, 78(11), 2779–2801. <https://doi.org/10.1253/circj.CJ-66-0098>
- Halcox, J. P. J., Schenke, W. H., Zalos, G., Mincemoyer, R., Prasad, A., Waclawiw, M. A., Nour, K. R. A., & Quyyumi, A. A. (2002). Prognostic Value of Coronary Vascular Endothelial Dysfunction. *Circulation*, 106(6), 653–658. <https://doi.org/10.1161/01.CIR.00000025404.78001.D8>
- Higgins, C. B., Wexler, L., Silverman, J. F., & Schroeder, J. S. (1976). Clinical and arteriographic features of Prinzmetal's variant angina: Documentation of etiologic factors. *The American Journal of Cardiology*, 37(6), 831–839. [https://doi.org/10.1016/0002-9149\(76\)90106-5](https://doi.org/10.1016/0002-9149(76)90106-5)
- JCS Joint Working Group. (2014). Guidelines for Diagnosis and Treatment of Patients With Vasospastic Angina (Coronary Spastic Angina) (JCS 2013). *Circulation Journal*, 78(11), 2779–2801. <https://doi.org/10.1253/circj.CJ-66-0098>
- Jespersen, L., Abildstrøm, S. Z., Hvelplund, A., & Prescott, E. (2013). Persistent angina: highly prevalent and associated with long-term anxiety, depression, low physical functioning, and quality of life in stable angina pectoris. *Clinical Research in Cardiology*, 102(8), 571–581. <https://doi.org/10.1007/s00392-013-0568-z>
- Jespersen, L., Hvelplund, A., Abildstrom, S. Z., Pedersen, F., Galatius, S., Madsen, J. K., Jorgensen, E., Kelbaek, H., & Prescott, E. (2012). Stable angina pectoris with no obstructive coronary artery disease is associated with increased risks of major adverse cardiovascular events. *European Heart Journal*, 33(6), 734–744. <https://doi.org/10.1093/eurheartj/ehr331>
- Kadokami, T., Shimokawa, H., Fukumoto, Y., Ito, A., Takayanagi, T., Egashira, K., & Takeshita, A. (1996). Coronary Artery Spasm Does Not Depend on the Intracellular Calcium Store but Is Substantially Mediated by the Protein Kinase C-Mediated Pathway in a Swine Model With Interleukin-1 β In Vivo. *Circulation*, 94(2), 190–196. <https://doi.org/10.1161/01.CIR.94.2.190>
- Kandabashi, T., Shimokawa, H., Miyata, K., Kunihiro, I., Kawano, Y., Fukata, Y.,

- Higo, T., Egashira, K., Takahashi, S., Kaibuchi, K., & Takeshita, A. (2000). Inhibition of Myosin Phosphatase by Upregulated Rho-Kinase Plays a Key Role for Coronary Artery Spasm in a Porcine Model With Interleukin-1 β . *Circulation*, *101*(11), 1319–1323. <https://doi.org/10.1161/01.CIR.101.11.1319>
- Kaski, J.-C., Crea, F., Gersh, B. J., & Camici, P. G. (2018). Reappraisal of Ischemic Heart Disease. *Circulation*, *138*(14), 1463–1480. <https://doi.org/10.1161/CIRCULATIONAHA.118.031373>
- Kaski, J. C., Crea, F., Meran, D., Rodriguez, L., Araujo, L., Chierchia, S., Davies, G., & Maseri, A. (1986). Local coronary supersensitivity to diverse vasoconstrictive stimuli in patients with variant angina. *Circulation*, *74*(6), 1255–1265. <https://doi.org/10.1161/01.CIR.74.6.1255>
- Kaski, J. C., Maseri, A., Vejar, M., Crea, F., Hackett, D., & Halson, P. (1989). Spontaneous coronary artery spasm in variant angina is caused by a local hyperreactivity to a generalized constrictor stimulus. *Journal of the American College of Cardiology*, *14*(6), 1456–1463. [https://doi.org/10.1016/0735-1097\(89\)90382-3](https://doi.org/10.1016/0735-1097(89)90382-3)
- KISHIDA, H., OTSU, F., SUZUKI, K., HATA, N., KUSAMA, Y., SUZUKI, T., NEJIMA, J., SAITO, T., & IIDA, N. (1985). Prominent negative u wave in variant angina pectoris. *Japanese Heart Journal*, *26*(6), 885–896. <https://doi.org/10.1536/ihj.26.885>
- KISHIDA, H., TADA, Y., FUKUMA, N., SAITOH, T., KUSAMA, Y., & SANOKI, J. (1996). Significant Characteristics of Variant Angina Patients with Associated Syncope. *Japanese Heart Journal*, *37*(3), 317–326. <https://doi.org/10.1536/ihj.37.317>
- Knuuti, J., Wijns, W., Saraste, A., Capodanno, D., Barbato, E., Funck-Brentano, C., Prescott, E., Storey, R. F., Deaton, C., Cuisset, T., Agewall, S., Dickstein, K., Edvardsen, T., Escaned, J., Gersh, B. J., Svitil, P., Gilard, M., Hasdai, D., Hatala, R., ... Clapp, B. (2020a). 2019 ESC Guidelines for the diagnosis and management of chronic coronary syndromes. *European Heart Journal*, *41*(3), 407–477. <https://doi.org/10.1093/eurheartj/ehz425>
- Knuuti, J., Wijns, W., Saraste, A., Capodanno, D., Barbato, E., Funck-Brentano, C., Prescott, E., Storey, R. F., Deaton, C., Cuisset, T., Agewall, S., Dickstein, K., Edvardsen, T., Escaned, J., Gersh, B. J., Svitil, P., Gilard, M., Hasdai, D., Hatala, R., ... Clapp, B. (2020b). 2019 ESC Guidelines for the

- diagnosis and management of chronic coronary syndromes. *European Heart Journal*, 41(3), 407–477. <https://doi.org/10.1093/eurheartj/ehz425>
- Konst, R. E., Damman, P., Pellegrini, D., Hartzema-Meijer, M. J., van Uden, B. J. C., Jansen, T. P. J., Brandsma, J., Vart, P., Gehlmann, H., Maas, A. H. E. M., van Royen, N., & Elias-Smale, S. E. (2021). Vasomotor dysfunction in patients with angina and nonobstructive coronary artery disease is dominated by vasospasm. *International Journal of Cardiology*, 333, 14–20. <https://doi.org/10.1016/j.ijcard.2021.02.079>
- Kuga, T., Shimokawa, H., Hirakawa, Y., Kadokami, Y., Arai, Y., Fukumoto, Y., Kuwata, K., Kozai, T., Egashira, K., & Takeshita, A. (2000). Increased Expression of L-Type Calcium Channels in Vascular Smooth Muscle Cells at Spastic Site in a Porcine Model of Coronary Artery Spasm. *Journal of Cardiovascular Pharmacology*, 35(5), 822–828. <https://doi.org/10.1097/00005344-200005000-00021>
- Kugiyama, K., Yasue, H., Okumura, K., Ogawa, H., Fujimoto, K., Nakao, K., Yoshimura, M., Motoyama, T., Inobe, Y., & Kawano, H. (1996). Nitric Oxide Activity Is Deficient in Spasm Arteries of Patients With Coronary Spastic Angina. *Circulation*, 94(3), 266–272. <https://doi.org/10.1161/01.CIR.94.3.266>
- Kunadian, V., Chieffo, A., Camici, P. G., Berry, C., Escaned, J., Maas, A. H. E. M., Prescott, E., Karam, N., Appelman, Y., Fraccaro, C., Louise Buchanan, G., Manzo-Silberman, S., Al-Lamee, R., Regar, E., Lansky, A., Abbott, J. D., Badimon, L., Duncker, D. J., Mehran, R., ... Baumbach, A. (2020). An EAPCI Expert Consensus Document on Ischaemia with Non-Obstructive Coronary Arteries in Collaboration with European Society of Cardiology Working Group on Coronary Pathophysiology & Microcirculation Endorsed by Coronary Vasomotor Disorders International Study Group. *European Heart Journal*, 41(37), 3504–3520. <https://doi.org/10.1093/eurheartj/ehaa503>
- Lablanche, J. M., Bauters, C., McFadden, E. P., Quandalle, P., & Bertrand, M. E. (1993). Potassium channel activators in vasospastic angina. *European Heart Journal*, 14(suppl B), 22–24. https://doi.org/10.1093/eurheartj/14.suppl_B.22
- Lanza, G. A. (2003). Increased platelet sodium-hydrogen exchanger activity in patients with variant angina. *Heart*, 89(8), 935–936. <https://doi.org/10.1136/heart.89.8.935>

- Lanza, G. A., Pedrotti, P., Pasceri, V., Lucente, M., Crea, F., & Maseri, A. (1996). Autonomic changes associated with spontaneous coronary spasm in patients with variant angina. *Journal of the American College of Cardiology*, 28(5), 1249–1256. [https://doi.org/10.1016/S0735-1097\(96\)00309-9](https://doi.org/10.1016/S0735-1097(96)00309-9)
- Masumoto, A., Mohri, M., Shimokawa, H., Urakami, L., Usui, M., & Takeshita, A. (2002). Suppression of Coronary Artery Spasm by the Rho-Kinase Inhibitor Fasudil in Patients With Vasospastic Angina. *Circulation*, 105(13), 1545–1547. <https://doi.org/10.1161/hc1002.105938>
- Miyata, K., Shimokawa, H., Higo, T., Yamawaki, T., Katsumata, N., Kandabashi, T., Tanaka, E., Takamura, Y., Yogo, K., Egashira, K., & Takeshita, A. (2000). Sarpogrelate, a Selective 5-HT_{2A} Serotonergic Receptor Antagonist, Inhibits Serotonin-Induced Coronary Artery Spasm in a Porcine Model. *Journal of Cardiovascular Pharmacology*, 35(2), 294–301. <https://doi.org/10.1097/00005344-200002000-00018>
- Mohri, M., Shimokawa, H., Hirakawa, Y., Masumoto, A., & Takeshita, A. (2003). Rho-kinase inhibition with intracoronary fasudil prevents myocardial ischemia in patients with coronary microvascular spasm. *Journal of the American College of Cardiology*, 41(1), 15–19. [https://doi.org/10.1016/S0735-1097\(02\)02632-3](https://doi.org/10.1016/S0735-1097(02)02632-3)
- Myerburg, R. J., Kessler, K. M., Mallon, S. M., Cox, M. M., deMarchena, E., Interian, A., & Castellanos, A. (1992). Life-Threatening Ventricular Arrhythmias in Patients with Silent Myocardial Ischemia Due to Coronary Artery Spasm. *New England Journal of Medicine*, 326(22), 1451–1455. <https://doi.org/10.1056/NEJM199205283262202>
- Nakayama, M., Yasue, H., Yoshimura, M., Shimasaki, Y., Kugiyama, K., Ogawa, H., Motoyama, T., Saito, Y., Ogawa, Y., Miyamoto, Y., & Nakao, K. (1999). T-786→C Mutation in the 5'-Flanking Region of the Endothelial Nitric Oxide Synthase Gene Is Associated With Coronary Spasm. *Circulation*, 99(22), 2864–2870. <https://doi.org/10.1161/01.CIR.99.22.2864>
- Newman, C. M., Maseri, A., Hackett, D. R., El-Tamimi, H. M., & Davies, G. J. (1990). Response of angiographically normal and atherosclerotic left anterior descending coronary arteries to acetylcholine. *The American Journal of Cardiology*, 66(15), 1070–1076. [https://doi.org/10.1016/0002-9149\(90\)90507-W](https://doi.org/10.1016/0002-9149(90)90507-W)

- Nishigaki, K., Inoue, Y., Yamanouchi, Y., Fukumoto, Y., Yasuda, S., Sueda, S., Urata, H., Shimokawa, H., & Minatoguchi, S. (2010). Prognostic Effects of Calcium Channel Blockers in Patients With Vasospastic Angina - A Meta-Analysis -. *Circulation Journal*, 74(9), 1943–1950. <https://doi.org/10.1253/circj.CJ-10-0292>
- Okumura, K., Yasue, H., Matsuyama, K., Goto, K., Miyag, H., Ogawa, H., & Matsuyama, K. (1988). Sensitivity and specificity of intracoronary injection of acetylcholine for the induction of coronary artery spasm. *Journal of the American College of Cardiology*, 12(4), 883–888. [https://doi.org/10.1016/0735-1097\(88\)90449-4](https://doi.org/10.1016/0735-1097(88)90449-4)
- Ong, P., Athanasiadis, A., Borgulya, G., Vokshi, I., Bastiaenen, R., Kubik, S., Hill, S., Schäufole, T., Mahrholdt, H., Kaski, J. C., & Sechtem, U. (2014). Clinical Usefulness, Angiographic Characteristics, and Safety Evaluation of Intracoronary Acetylcholine Provocation Testing Among 921 Consecutive White Patients With Unobstructed Coronary Arteries. *Circulation*, 129(17), 1723–1730. <https://doi.org/10.1161/CIRCULATIONAHA.113.004096>
- Ong, P., Athanasiadis, A., Mahrholdt, H., Borgulya, G., Sechtem, U., & Kaski, J. C. (2012). Increased coronary vasoconstrictor response to acetylcholine in women with chest pain and normal coronary arteriograms (cardiac syndrome X). *Clinical Research in Cardiology*, 101(8), 673–681. <https://doi.org/10.1007/s00392-012-0442-4>
- Ong, P., Athanasiadis, A., & Sechtem, U. (2013). Patterns of coronary vasomotor responses to intracoronary acetylcholine provocation. *Heart*, 99(17), 1288–1295. <https://doi.org/10.1136/heartjnl-2012-302042>
- Ong, P., Camici, P. G., Beltrame, J. F., Crea, F., Shimokawa, H., Sechtem, U., Kaski, J. C., & Bairey Merz, C. N. (2018). International standardization of diagnostic criteria for microvascular angina. *International Journal of Cardiology*, 250, 16–20. <https://doi.org/10.1016/j.ijcard.2017.08.068>
- Perera, D., Berry, C., Hoole, S. P., Sinha, A., Rahman, H., Morris, P. D., Kharbanda, R. K., Petraco, R., & Channon, K. (2023a). Invasive coronary physiology in patients with angina and non-obstructive coronary artery disease: a consensus document from the coronary microvascular dysfunction workstream of the British Heart Foundation/National Institute for Health Research Partnership. *Heart*, 109(2), 88–95.

- <https://doi.org/10.1136/heartjnl-2021-320718>
- Perera, D., Berry, C., Hoole, S. P., Sinha, A., Rahman, H., Morris, P. D., Kharbada, R. K., Petraco, R., & Channon, K. (2023b). Invasive coronary physiology in patients with angina and non-obstructive coronary artery disease: a consensus document from the coronary microvascular dysfunction workstream of the British Heart Foundation/National Institute for Health Research Partnership. *Heart*, *109*(2), 88–95. <https://doi.org/10.1136/heartjnl-2021-320718>
- Prinzmetal, M., Kenamer, R., Merliss, R., Wada, T., & Bor, N. (1959a). Angina pectoris I. A variant form of angina pectoris. *The American Journal of Medicine*, *27*(3), 375–388. [https://doi.org/10.1016/0002-9343\(59\)90003-8](https://doi.org/10.1016/0002-9343(59)90003-8)
- Prinzmetal, M., Kenamer, R., Merliss, R., Wada, T., & Bor, N. (1959b). Angina pectoris I. A variant form of angina pectoris. *The American Journal of Medicine*, *27*(3), 375–388. [https://doi.org/10.1016/0002-9343\(59\)90003-8](https://doi.org/10.1016/0002-9343(59)90003-8)
- Recio-Mayoral, A., Rimoldi, O. E., Camici, P. G., & Kaski, J. C. (2013). Inflammation and Microvascular Dysfunction in Cardiac Syndrome X Patients Without Conventional Risk Factors for Coronary Artery Disease. *JACC: Cardiovascular Imaging*, *6*(6), 660–667. <https://doi.org/10.1016/j.jcmg.2012.12.011>
- Reriani, M., Raichlin, E., Prasad, A., Mathew, V., Pumper, G. M., Nelson, R. E., Lennon, R., Rihal, C., Lerman, L. O., & Lerman, A. (2010). Long-Term Administration of Endothelin Receptor Antagonist Improves Coronary Endothelial Function in Patients With Early Atherosclerosis. *Circulation*, *122*(10), 958–966. <https://doi.org/10.1161/CIRCULATIONAHA.110.967406>
- Sara, J. D., Widmer, R. J., Matsuzawa, Y., Lennon, R. J., Lerman, L. O., & Lerman, A. (2015). Prevalence of Coronary Microvascular Dysfunction Among Patients With Chest Pain and Nonobstructive Coronary Artery Disease. *JACC: Cardiovascular Interventions*, *8*(11), 1445–1453. <https://doi.org/10.1016/j.jcin.2015.06.017>
- Satoh, S., Tomoike, H., Mitsuoka, W., Egashira, S., Tagawa, H., Kuga, T., & Nakamura, M. (1990). Smooth muscles from spastic coronary artery segments show hypercontractility to histamine. *American Journal of Physiology-Heart and Circulatory Physiology*, *259*(1), H9–H13.

- <https://doi.org/10.1152/ajpheart.1990.259.1.H9>
- Shimokawa, H. (2000). Cellular and Molecular Mechanisms of Coronary Artery Spasm. *Japanese Circulation Journal*, 64(1), 1–12. <https://doi.org/10.1253/jcj.64.1>
- Shimokawa, H., Suda, A., Takahashi, J., Berry, C., Camici, P. G., Crea, F., Escaned, J., Ford, T., Yui, E., Kaski, J. C., Kiyooka, T., Mehta, P. K., Ong, P., Ozaki, Y., Pepine, C., Rimoldi, O., Safdar, B., Sechtem, U., Tsujita, K., ... Merz, C. N. B. (2021). Clinical characteristics and prognosis of patients with microvascular angina: an international and prospective cohort study by the Coronary Vasomotor Disorders International Study (COVADIS) Group. *European Heart Journal*, 42(44), 4592–4600. <https://doi.org/10.1093/eurheartj/ehab282>
- Sinha, A., Rahman, H., & Perera, D. (2020). Coronary microvascular disease: current concepts of pathophysiology, diagnosis and management. *Cardiovascular Endocrinology & Metabolism*, 10(1), 22–30. <https://doi.org/10.1097/XCE.0000000000000223>
- Tonet, E., Pompei, G., Faragasso, E., Cossu, A., Pavasini, R., Passarini, G., Tebaldi, M., & Campo, G. (2021). Coronary Microvascular Dysfunction: PET, CMR and CT Assessment. *Journal of Clinical Medicine*, 10(9), 1848. <https://doi.org/10.3390/jcm10091848>
- Toyo-oka, T., Aizawa, T., Suzuki, N., Hirata, Y., Miyauchi, T., Shin, W. S., Yanagisawa, M., Masaki, T., & Sugimoto, T. (1991). Increased plasma level of endothelin-1 and coronary spasm induction in patients with vasospastic angina pectoris. *Circulation*, 83(2), 476–483. <https://doi.org/10.1161/01.CIR.83.2.476>
- Yamamoto, H., Yoshimura, H., Noma, M., Kai, H., Suzuki, S., Tajimi, T., Sugihara, M., & Kikuchi, Y. (1992). Preservation of endothelium-dependent vasodilation in the spastic segment of the human epicardial coronary artery by substance P. *American Heart Journal*, 123(2), 298–303. [https://doi.org/10.1016/0002-8703\(92\)90638-C](https://doi.org/10.1016/0002-8703(92)90638-C)
- YASUE, H., & KUGIYAMA, K. (1997). Coronary Spasm: Clinical Features and Pathogenesis. *Internal Medicine*, 36(11), 760–765. <https://doi.org/10.2169/internalmedicine.36.760>
- Yasue, H., Nakagawa, H., Itoh, T., Harada, E., & Mizuno, Y. (2008). Coronary artery spasm—Clinical features, diagnosis, pathogenesis, and treatment. *Journal of Cardiology*, 51(1), 2–17.

<https://doi.org/10.1016/j.jjcc.2008.01.00>

1